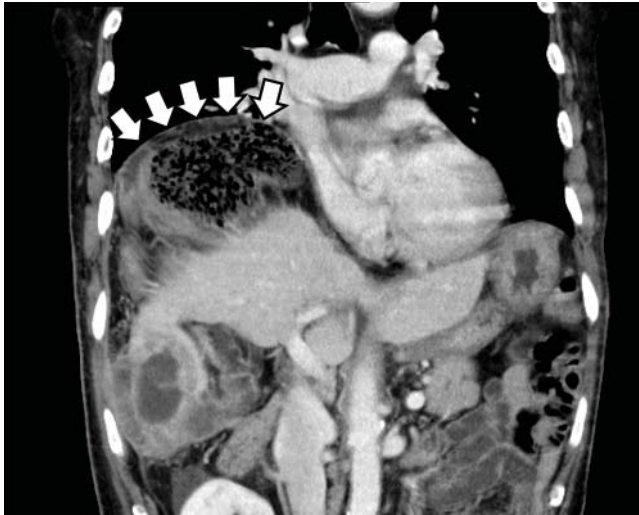


## Gas under the right diaphragm

FEBRUARY 2018

In the article “Gas under the right diaphragm” (Matsura H, Hata H. *Cleve Clin J Med* 2018; 85[2]:98–100), **Figure 2** appeared upside down. It should have appeared as follows:



**Figure 2.** The Chilaiditi sign on computed tomography, with volvulus of the cecum between the diaphragm and liver and a closed-loop obstruction (arrows).

The correction has been made to the online version at [www.ccm.org](http://www.ccm.org).

## Physical examination in dyspnea

DECEMBER 2017

On page 949 of the article “Diagnostic value of the physical examination in patients with dyspnea” (Shellenberger RA, Balakrishnan B, Avula S, Ebel A, Shaik S. *Cleve Clin J Med* 2017; 84[12]:943–950), the terms “abdominojugular reflex” and “hepatojugular reflex” should have been “abdominojugular reflux” and “hepatojugular reflux.” This error also occurred in **Table 5** on that page. The correction has been made to the online version at [www.ccm.org](http://www.ccm.org).