

TABLE OF CONTENTS

FROM THE EDITOR 346

The algorithm less traveled **346**

At Bellevue, the RPR was a routine test; at the University of Pennsylvania not so much—it all depends on context.

B.F. MANDELL

THE CLINICAL PICTURE..... 352

An unusual complication of peritoneal dialysis **352**

A 45-year-old man, on peritoneal dialysis for 15 years, presented with abdominal pain, nausea, vomiting, and fever.

M. HANOUNEH, P. DAMERA, M. FETRAT, AND D. GEETHA

THE CLINICAL PICTURE..... 356

Eyes of the mimicker **356**

A 42-year-old man presented with intermittent fevers, rigors, headache, and myalgia, and now, one-sided vision loss.

T.A. SUSSMAN, N.K. SHRESTHA, AND M. MIKLOWSKI

1-MINUTE CONSULT 362

How soon should patients with infective endocarditis be referred for valve surgery? **362**

Refer sooner rather than later if the patient has heart failure, uncontrolled infection, or embolic risk.

M. SOUD, H. MOUSSA PACHA, AND M. CHADI ALRAIES

EDITORIAL 365

Infective endocarditis: Refer for expert team care as soon as possible **365**

Infectious endocarditis needs multidisciplinary care. If surgery is indicated, it is best done sooner.

G.B. PETERSSON, B. GRIFFIN, S.M. GORDON, AND E.H. BLACKSTONE



MEDICAL GRAND ROUNDS 367

What you can do for your fibromyalgia patient **367**

Fibromyalgia is a defined syndrome of neuronal dysregulation and can be diagnosed and managed in a primary care setting.

C.E. GOTA

CONTINUED ON PAGE 344

Online Features

Access

Cleveland Clinic Journal of Medicine content is readily available to all and is free of charge at www.ccjm.org. On your first visit, we will ask you to take a few minutes to register, but subsequent visits will be unencumbered except for an occasional request for your e-mail address when you visit using another device (eg, mobile phone, tablet).

Services

- Navigate quickly to articles in current and past issues via links on the home page and pull-down menus at the top of the page. Use the search function to find a specific article, or browse by topic or article type.
- Continuing medical education activities are accessible from article links and from a CME pull-down menu on the home page. Participation is free.
- Follow links on the home page to news, summaries of recent scientific meetings, and interactive quizzes.
- Click on the PDF symbol at the top of any online article to read, download, or print the article in PDF format.

Social Networking

To post a *CCJM* article to Facebook or Twitter, just click on the icon at the top of any online article.

www.ccjm.org

CONTINUED FROM PAGE 342

CME CREDIT REVIEW 377

Idiopathic pulmonary fibrosis: What primary care physicians need to know

This devastating and fatal lung disease generally affects older adults, especially men, and can be mistaken for COPD.

L.B. TOLLE, B.D. SOUTHERN, D.A. CULVER, AND J.C. HOROWITZ

EDITORIAL 387

It takes a village to care for the patient with idiopathic pulmonary fibrosis

The primary care physician can play key roles in diagnosis, referral, and long-term management.

A. FISCHER

CME CREDIT REVIEW 390

Genitourinary syndrome of menopause: Common problem, effective treatments

Half of all postmenopausal women experience these symptoms. Most do not seek relief.

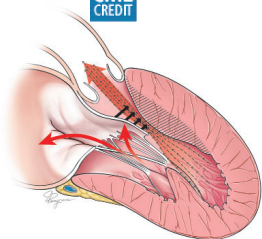
N.A. PHILLIPS AND G.A. BACHMANN

CME CREDIT REVIEW 399

Hypertrophic cardiomyopathy: A complex disease

Most people who carry its mutations are never affected, but, rarely, some patients die suddenly at a young age.

L. YOUNG, N.G. SMEDIRA, A. TOWER-RADER, H. LEVER, AND M.Y. DESAI



DEPARTMENTS 389

CME Calendar

Letters to the Editor

A reader comments on acute cardiorenal syndrome (March 2018).

CME Instructions

Upcoming Features

- Thoracic aortic aneurysm: How to counsel, when to refer
- Should we supplement calcium and vitamin D?
- Renal disease in surgical patients: Minimizing the impact
- Life after critical care: The journey forward
- Traveling while diabetic: A survival guide
- Hydroxychloroquine: Old drug, new relevance
- Women with diabetes: Special concerns
- Cardiac rehabilitation: A class I recommendation

