

THE CLINICAL PICTURE

TAKANOBU HIROSAWA, MD

Attending Physician, Department of Diagnostic and Generalist Medicine, Dokkyo Medical University, Tochigi, Japan

TARO SHIMIZU, MD, MPH, MBA

Chairman, Department of Diagnostic and Generalist Medicine, Dokkyo Medical University, Tochigi, Japan

Osmotic demyelination syndrome due to hyperosmolar hyperglycemia

A 55-YEAR-OLD MAN with a 20-year history of type 2 diabetes mellitus was admitted to the hospital after presenting to the emergency department with an acute change in mental status. Three days earlier, he had begun to feel abdominal discomfort and dizziness, which gradually worsened.

On presentation, his Glasgow Coma Scale score was 13 out of 15 (eye-opening response 3 of 4, verbal response 4 of 5, motor response 6 of 6), his blood pressure was 221/114 mm Hg, and other vital signs were normal. Physical examination including a neurologic examination was normal. No gait abnormality or ataxia was noted.

When asked about current medications, he said that 2 years earlier he had missed an appointment with his primary care physician and so had never obtained refills of his diabetes medications.

Results of laboratory testing were as follows:

- Blood glucose 1,011 mg/dL (reference range 65–110)
- Hemoglobin A_{1c} 17.8% (4%–5.6%)
- Sodium 126 mmol/L (135–145)
- Sodium corrected for serum glucose 141 mmol/L
- Potassium 3.2 mmol/L (3.5–5.0)
- Blood urea nitrogen 43.8 mg/dL (8–21)
- Calculated serum osmolality 324 mosm/kg (275–295).

Blood gas analysis showed no acidosis. Tests for urinary and serum ketones were negative. Computed tomography (CT) of the head without contrast was normal.

Based on the results of the evaluation, the patient's condition was diagnosed as a hyperosmolar hyperglycemic state, presumably from dehydration and noncompliance with dia-

doi:10.3949/ccjm.85a.17020

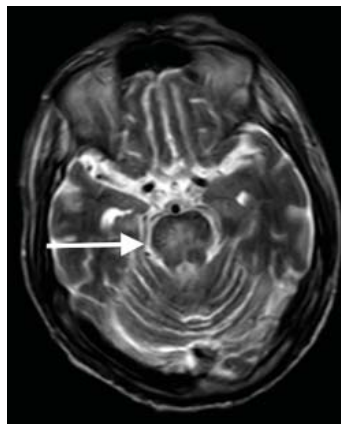


Figure 1. Axial T2-weighted magnetic resonance imaging on hospital day 5 showed a lesion with high signal intensity in the pons (arrow).

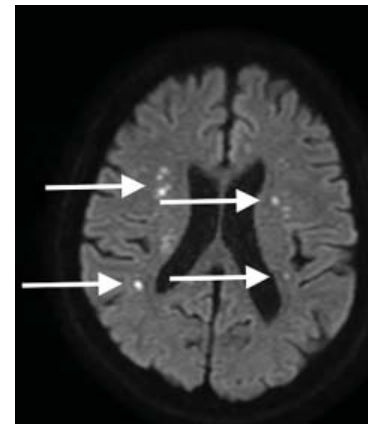


Figure 2. Axial diffusion-weighted magnetic resonance imaging on hospital day 5 showed multiple lesions with high signal intensity in both cerebral hemispheres (arrows).

betes medications. His altered mental status was also attributed to this diagnosis. He was started on aggressive hydration and insulin infusion to correct the blood glucose level. Repeat laboratory testing 7 hours after admission revealed a blood glucose of 49 mg/dL, sodium 148 mmol/L, blood urea nitrogen 43 mg/dL, and calculated serum osmolality 290 mosm/kg.

The insulin infusion was suspended, and glucose infusion was started. With this treatment, his blood glucose level stabilized, but his Glasgow Coma Scale score was unchanged from the time of presentation. A neurologic examination at this time showed bilateral dysmetria. Cranial nerves were normal. Motor examination showed normal tone with a Medical Research Council score of 5 of 5 in all extremities. Sensory examination revealed

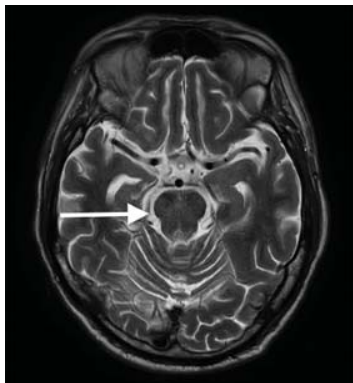


Figure 3. Axial T2-weighted magnetic resonance imaging repeated several months after presentation showed an improved lesion in the pons (arrow).

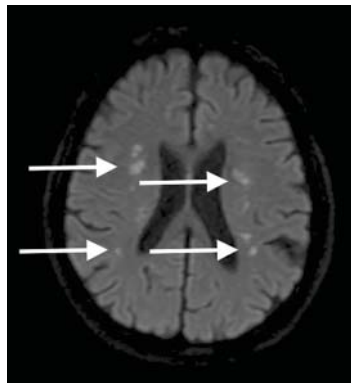


Figure 4. On diffusion-weighted magnetic resonance imaging several months after presentation, the multiple lesions in both hemispheres (arrows) were almost unchanged.

a glove-and-stocking pattern of loss of vibratory sensation. Tendon reflexes were normal except for diminished bilateral knee-jerk and ankle-jerk responses.

On hospital day 5, T2-weighted magnetic resonance imaging (MRI) of the brain showed central pontine hyperintensity with peripheral sparing (**Figure 1**), while diffusion-weighted MRI revealed multiple lesions with high signal intensity in both hemispheres (**Figure 2**)—findings consistent with osmotic demyelination syndrome.

Over several weeks, his blood glucose level was gradually corrected from 300 mg/dL to a normal range. His altered mental status and dysmetria resolved, and repeat neurologic examinations over several months were normal. During this same time, the multiple bihemispheric lesions seen on T2-weighted MRI normalized, but the findings on diffusion-weighted MRI remained almost unchanged (**Figures 3 and 4**).

■ OSMOTIC DEMYELINATION SYNDROME

Osmotic demyelination syndrome is a rare but life-threatening neurologic disorder caused by damage to the myelin sheath of brain cells.¹ It is well recognized to occur particularly in rapid correction of severe hyponatremia.² It was first described by Adams et al in 1959 in patients with alcoholism or malnutrition.³

The syndrome includes 3 variations of myelinolysis: central pontine myelinolysis alone, extrapontine myelinolysis alone, and the 2 together.⁴ Although the exact pathogenesis of osmotic demyelination syndrome is still unclear, rapid correction of chronic hyponatremia, alcoholism, cirrhosis, malnutrition, liver transplant, and severe burns have been described as triggers.⁴

Central pontine myelinolysis is a pivotal manifestation of the syndrome and is characterized by progressive lethargy, quadriplegia, dysarthria, ophthalmoplegia, dysphasia, ataxia, and reflex changes. Clinical symptoms of extrapontine myelinolysis are variable.⁴

Although CT may underestimate osmotic demyelination syndrome, the typical radiologic findings on brain MRI are hyperintense lesions in the central pons or associated extrapontine structures on T2-weighted and fluid-attenuated inversion recovery sequences.⁴

A precise definition of hyperosmolar hyperglycemia does not exist. The Joint British Diabetes Societies for Inpatient Care suggested the following features: a measured osmolality of 320 mosm/kg or higher, a blood glucose level of 541 mg/dL or higher, severe dehydration, and feeling unwell.⁵

Our patient's clinical course and high hemoglobin A_{1c} suggested prolonged hyperglycemia and high serum osmolality before his admission. After his admission, aggressive hydration and insulin therapy corrected the hyperglycemia and serum osmolality too rapidly for his brain cells to adjust to the change. It was reasonable to suspect a hyperosmolar hyperglycemic state as one of the main causes of his mental status change and ataxia. This, along with lack of improvement in his impaired mental status and new-onset ataxia despite treatment, led to suspicion of osmotic demyelination syndrome. His diminished bilateral knee-jerk and ankle-jerk responses more likely represented diabetic neuropathy rather than osmotic demyelination syndrome.

Osmotic demyelination syndrome has seldom been reported as a complication of hyperosmolar hyperglycemia.⁶⁻¹³ And extrapontine myelinolysis with hyperosmolar hyperglycemia is extremely rare, with only 2 reports to date to the best of our knowledge.^{6,10}

Rapid correction of chronic hyponatremia can trigger osmotic demyelination syndrome

There is no specific treatment for osmotic demyelination syndrome except for supportive care and treatment of coexisting conditions. Once an osmotic derangement is identified, we recommend correcting chronically elevated serum glucose values gradually to avoid overtreatment, just as we would do with elevated serum sodium levels. Changes in neurologic findings, serum blood glucose level, and serum osmolality should be followed closely. A review showed that a favorable recovery from osmotic demyelination syndrome is possible even with severe neurologic deficits.⁴

REFERENCES

1. **Brown WD.** Osmotic demyelination disorders: central pontine and extrapontine myelinolysis. *Curr Opin Neurol* 2000; 13(6):691–697. pmid:11148672
2. **Lauren R, Karp BI.** Myelinolysis after correction of hyponatremia. *Ann Intern Med* 1997; 126(1):57–62. pmid: 8992924
3. **Adams RD, Victor M, Mancall EL.** Central pontine myelinolysis: a hitherto undescribed disease occurring in alcoholic and malnourished patients. *AMA Arch Neurol Psychiatry* 1959; 81(2):154–172. pmid: 13616772
4. **Singh TD, Fugate JE, Rabinstein AA.** Central pontine and extrapontine myelinolysis: a systematic review. *Eur J Neurol* 2014; 21(12):1443–1450. doi:10.1111/ene.1257
5. **Scott AR; Joint British Diabetes Societies (JBDS) for Inpatient Care; JBDS Hyperosmolar Hyperglycaemic Guidelines Group.** Management of hyperosmolar hyperglycaemic state in adults with diabetes. *Diabet Med* 2015; 32(6):714–724. doi:10.1111/dme.12757
6. **McComb RD, Pfeiffer RF, Casey JH, Wolcott G, Till DJ.** Lateral pontine and extrapontine myelinolysis associated with hypernatremia and hyperglycemia. *Clin Neuropathol* 1989; 8(6):284–288. pmid:2695277
7. **O'Malley G, Moran C, Draman MS, et al.** Central pontine myelinolysis complicating treatment of the hyperglycaemic hyperosmolar state. *Ann Clin Biochem* 2008; 45(pt 4):440–443. doi:10.1258/acb.2008.00717
8. **Burns JD, Kosa SC, Wijidicks EF.** Central pontine myelinolysis in a patient with hyperosmolar hyperglycemia and consistently normal serum sodium. *Neurocrit Care* 2009; 11(2):251–254. doi:10.1007/s12028-009-9241-9
9. **Mao S, Liu Z, Ding M.** Central pontine myelinolysis in a patient with epilepsy partialis continua and hyperglycaemic hyperosmolar state. *Ann Clin Biochem* 2011; 48(pt 1):79–82. doi:10.1258/acb.2010.010152. Epub 2010 Nov 23.
10. **Guerrero WR, Dababneh H, Nadeau SE.** Hemiparesis, encephalopathy, and extrapontine osmotic myelinolysis in the setting of hyperosmolar hyperglycemia. *J Clin Neurosci* 2013; 20(6):894–896. doi:10.1016/j.jocn.2012.05.045
11. **Hegazi MO, Mashankar A.** Central pontine myelinolysis in the hyperosmolar hyperglycaemic state. *Med Princ Pract* 2013; 22(1):96–99. doi:10.1159/000341718
12. **Rodríguez-Velver KV, Soto-García AJ, Zapata-Rivera MA, Montes-Villarreal J, Villarreal-Pérez JZ, Rodríguez-Gutiérrez R.** Osmotic demyelination syndrome as the initial manifestation of a hyperosmolar hyperglycemic state. *Case Rep Neurol Med* 2014; 2014:652523. doi:10.1155/2014/652523
13. **Chang YM.** Central pontine myelinolysis associated with diabetic hyperglycemia. *JSM Clin Case Rep* 2014; 2(6):1059.

ADDRESS: Takanobu Hirose, MD, Department of Diagnostic and Generalist Medicine, Dokkyo Medical University, 6th Floor, Kyoiku-Iryou to, Mibu-Machi, Shimotsuga-Gun, Tochigi, 321-0293, Japan; t.hirosawa1983@gmail.com

TAKE-AWAY POINTS

- Osmotic demyelination syndrome is a rare but severe complication of a hyperosmolar hyperglycemic state.
- Physicians should be aware not only of changes in serum sodium, but also of changes in serum osmolality and serum glucose.
- When a new-onset neurologic deficit is found during treatment of a hyperosmolar hyperglycemic state, suspect osmotic demyelination syndrome, monitor changes in serum osmolality, and consider brain MRI.