

TABLE OF CONTENTS

FROM THE EDITOR

MGUS: It's about the protein, not just the marrow **4**

What is a cause of a high erythrocyte sedimentation rate with a normal C-reactive protein and a low anion gap?

B.F. MANDELL

THE CLINICAL PICTURE

Acute-onset quadriplegia with hyperreflexia **7**

MRI showed diffuse T2 hyperintensity beginning at the level of the medulla and extending to the level of C7.

N. SHAIKH, M. SARDAR, W. KHAN, AND W. GHALI

THE CLINICAL PICTURE

Emphysematous cystitis **10**

The patient had fallen in her home and remained on the floor for 2 days until neighbors heard her cries and called 911.

W. ABUSNINA, M. SHEHATA, S. NASSRI, AND F. ZEID

1-MINUTE CONSULT

When can I stop dual antiplatelet therapy in patients with drug-eluting stents? **13**

The decision requires balancing the risk of thrombosis against the risk of bleeding. A cardiologist can help.

J.S. RICO-MESA, C. URIBE, M. PRASAD, AND S.A. LUIS

1-MINUTE CONSULT

Should metformin be used in every patient with type 2 diabetes? **17**

Most patients should receive it, with exceptions. Nevertheless, it is underused.

V. MAKIN AND M.C. LANSANG

SYMPTOMS TO DIAGNOSIS



Rapidly progressive pleural effusion **21**

A 33-year-old nonsmoker presents with severe pleuritic chest pain; the differential diagnosis is broad.

Z. ZOOMOT, A.S. WAHLA, AND S. FARHA

Online Features

Access

Cleveland Clinic Journal of Medicine content is readily available to all and is free of charge at www.ccjm.org.

Services

- Navigate quickly to articles in current and past issues via links on the home page and pull-down menus at the top of the page. Use the search function to find a specific article, or browse by topic or article type.
- Continuing medical education and maintenance of certification activities are accessible from article links and from a CME pull-down menu on the home page. Participation is free.
- Follow links on the home page to news, summaries of recent scientific meetings, and interactive quizzes.
- Click on the PDF symbol at the top of any online article to read, download, or print the article in PDF format.

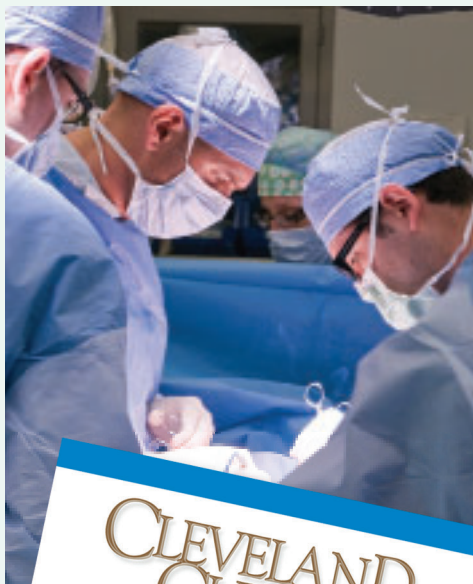Social Networking

To post a *CCJM* article to Facebook or Twitter, just click on the icon at the top of any online article.

www.ccjm.org

Upcoming Features

- Heart failure guidelines: What you need to know
- Subclinical hypothyroidism: When should it be treated?
- Managing malignant pleural effusion
- Should a positive blood culture be repeated?
- Human papillomavirus update: Defeating cervical cancer
- Detecting fibrosis in hepatitis C and fatty liver disease
- Postural tachycardia: Evaluation and management
- Interpreting the CBC
- Smart imaging for syncope



CLEVELAND
CLINIC
JOURNAL OF
MEDICINE

JANUARY 2019

TALL ROUNDS®

Progress in diagnosing and managing cardiac amyloidosis 29

Early diagnosis can often be made noninvasively; new treatments are effective and well-tolerated.

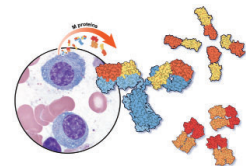
M. HANNA, C. HUDED, E.R. RODRIGUEZ, D. PHELAN, D. KWON, W. JABER, J. VALENT, AND M.Z.-Y. TONG

REVIEW

Monoclonal gammopathy of undetermined significance: A primary care guide 39

Low-risk MGUS may not require subspecialty referral and can be followed by the outpatient provider.

J. KHOURI, C. SAMARAS, J. VALENT, A.M. GARCIA, B. FAIMAN, S. MATHUR, K. HAMILTON, M. NAKASHIMA, AND M. KALAYCIO



REVIEW

Hypertension guidelines: Treat patients, not numbers 47

When treating high blood pressure, how low should we try to go? Debate continues.

W. ALEYADEH, E. HUTT-CENTENO, H.M. AHMED, AND N.P. SHAH

REVIEW

Common benign breast concerns for the primary care physician 57

Because breast cancer is so common, women with breast problems often fear the worst. They needn't.

C.L. KLASSEN, S.L. HINES, AND K. GHOSH

REVIEW

Who needs to carry an epinephrine autoinjector? 66

Patients who have had anaphylaxis or who are at risk of it should carry an epinephrine autoinjector with them at all times.

T.T. SONG AND P. LIEBERMAN

DEPARTMENTS

CME Calendar 6

CME/MOC Instructions Inside back cover