

# Monoclonal gammopathy of undetermined significance: A primary care guide

## ABSTRACT

Monoclonal gammopathy of undetermined significance (MGUS) is commonly diagnosed in outpatients being worked up for an array of clinical concerns. It carries a risk of progression to myeloma and other lymphoproliferative disorders that, albeit low (1% per year), warrants regular follow-up. Patients with MGUS can be risk-stratified on the basis of the amount and type of their monoclonal protein as well as whether they have an abnormal light-chain ratio. Here, we provide a guide to the diagnosis, workup, and management of MGUS.

## KEY POINTS

MGUS is the most common of the monoclonal gammopathies.

The overall risk of MGUS progressing to myeloma and other lymphoproliferative disorders is 1% per year.

Low-risk MGUS is defined by an immunoglobulin G monoclonal protein at a concentration less than 1.5 g/dL and a normal serum free light-chain ratio.

Low-risk MGUS carries a much lower risk of progression than intermediate- and high-risk MGUS, may not require subspecialty referral, and can be followed by the outpatient provider.

**T**HE MONOCLONAL GAMMOPATHIES encompass a number of disorders characterized by the production of a monoclonal protein (M protein) by an abnormal clone of plasma cells or other lymphoid cells. Monoclonal gammopathy of undetermined significance (MGUS) is the most common of these disorders. The diagnostic criteria for MGUS are listed in **Table 1**.

Dr. Valent has disclosed teaching and speaking for Amgen, Celgene, and Takeda.

doi:10.3949/ccjm.86a.17133

Its clinical relevance lies in the inherent risk of progression to hematologic malignancies such as multiple myeloma or other lymphoproliferative disorders, or of organ dysfunction due to the toxic effects of the M protein. An M protein may consist of an intact immunoglobulin (Ig) molecule—ie, 2 light chains and 2 heavy chains (most commonly IgG type followed by IgA and IgM)—or a light chain only (kappa or lambda) (**Figure 1**).

MGUS is present in 3% to 4% of the popu-

### JACK KHOURI, MD

Department of Hematology and Medical Oncology, Taussig Cancer Institute, Cleveland Clinic

### CHRISTY SAMARAS, DO

Department of Hematology and Medical Oncology, Taussig Cancer Institute, Cleveland Clinic; Clinical Assistant Professor, Cleveland Clinic Lerner College of Medicine of Case Western Reserve University, Cleveland, OH

### JASON VALENT, MD

Department of Hematology and Medical Oncology, Taussig Cancer Institute, Cleveland Clinic; Clinical Assistant Professor, Cleveland Clinic Lerner College of Medicine of Case Western Reserve University, Cleveland, OH

### ALEX MEJIA GARCIA, MD

Department of Hematology and Medical Oncology, Taussig Cancer Institute, Cleveland Clinic

### BETH FAIMAN, PhD, CNP

Department of Hematologic Oncology and Blood Disorders, Taussig Cancer Institute, Cleveland Clinic

### SAVETA MATHUR, CNP

Department of Hematology and Medical Oncology, Taussig Cancer Institute, Cleveland Clinic

### KIM HAMILTON, CNP

Department of Hematology and Medical Oncology, Taussig Cancer Institute, Cleveland Clinic

### MEGAN NAKASHIMA, MD

Department of Clinical Pathology, Cleveland Clinic; Assistant Professor, Cleveland Clinic Lerner College of Medicine of Case Western Reserve University, Cleveland, OH

### MATT KALAYCIO, MD

Chairman, Department of Hematology and Medical Oncology, Bone Marrow Transplant Program; Transplantation Center, and Department of Cancer Biology, Taussig Cancer Institute, Cleveland Clinic; Professor, Cleveland Clinic Lerner College of Medicine of Case Western Reserve University, Cleveland, OH

TABLE 1

**Diagnostic criteria for MGUS, smoldering multiple myeloma, and active multiple myeloma**

**Monoclonal gammopathy of undetermined significance (MGUS)**

Serum monoclonal (M) protein < 3 g/dL  
Clonal bone marrow plasma cells < 10%<sup>a</sup>  
Absence of myeloma-defining events or light-chain amyloidosis

**Smoldering multiple myeloma**

Serum M protein ≥ 3 g/dL or clonal bone marrow plasma cells 10%–60%, or both  
Absence of myeloma-defining events or light-chain amyloidosis

**Symptomatic multiple myeloma**

Clonal bone marrow plasma cells ≥ 10%  
or plasmacytoma and ≥ 1 myeloma-defining event:  
**Calcium:** hypercalcemia, ie, serum calcium > 1 mg/dL higher than the upper limit of normal or > 11 mg/dL  
**Renal insufficiency:** creatinine clearance < 40 mL/minute or serum creatinine > 2 mg/dL  
**Anemia:** hemoglobin > 2 g/dL below the lower limit of normal, or < 10 g/dL  
**Bone involvement:** ≥ 1 lytic lesions on skeletal radiography, computed tomography, or positron emission tomography–computed tomography  
Clonal bone marrow plasma cell percentage ≥ 60%  
Involved: uninvolved serum free light chain ratio ≥ 100 with involved free light chain ≥ 100 mg/L  
More than 1 focal lesion on magnetic resonance imaging<sup>b</sup>

<sup>a</sup> Can be omitted in patients with low-risk MGUS.

<sup>b</sup> As opposed to diffuse lesions (diffuse marrow infiltration). Magnetic resonance imaging of the whole body—or at least of the spine and pelvis if whole-body imaging is not feasible—is preferred. Lesions should be > 5 mm in size.

Based on information in reference 7.

lation over age 50 and is more common in older men, African Americans, and Africans.<sup>1–6</sup>

The overall risk of progression to myeloma and related disorders is less than or equal to 1% per year depending on the subtype of the M protein (higher risk with IgM than non-IgM and light-chain MGUS).<sup>7,8</sup> While the

risk of malignant transformation is low, multiple myeloma is almost always preceded by the presence of an asymptomatic and often unrecognized monoclonal protein.

**■ WHEN SHOULD WE LOOK FOR AN M PROTEIN?**

An M protein is typically an incidental finding when a patient is being assessed for any of a number of presenting symptoms or conditions. A large retrospective study<sup>9</sup> found that screening for MGUS was mostly performed by internal medicine physicians. The indications for testing were anemia, bone-related issues, elevated creatinine, elevated erythrocyte sedimentation rate, and neuropathy.

Routine screening for an M protein in the absence of clinical suspicion is not recommended, given the low risk of malignant progression, lack of effect on patient outcomes, the accompanying emotional burden, and lack of treatment options.<sup>5,10</sup> Evaluation for monoclonal gammopathy may be considered as part of the workup of associated clinical symptoms and signs and laboratory and imaging findings (Table 2).<sup>2,10,11</sup>

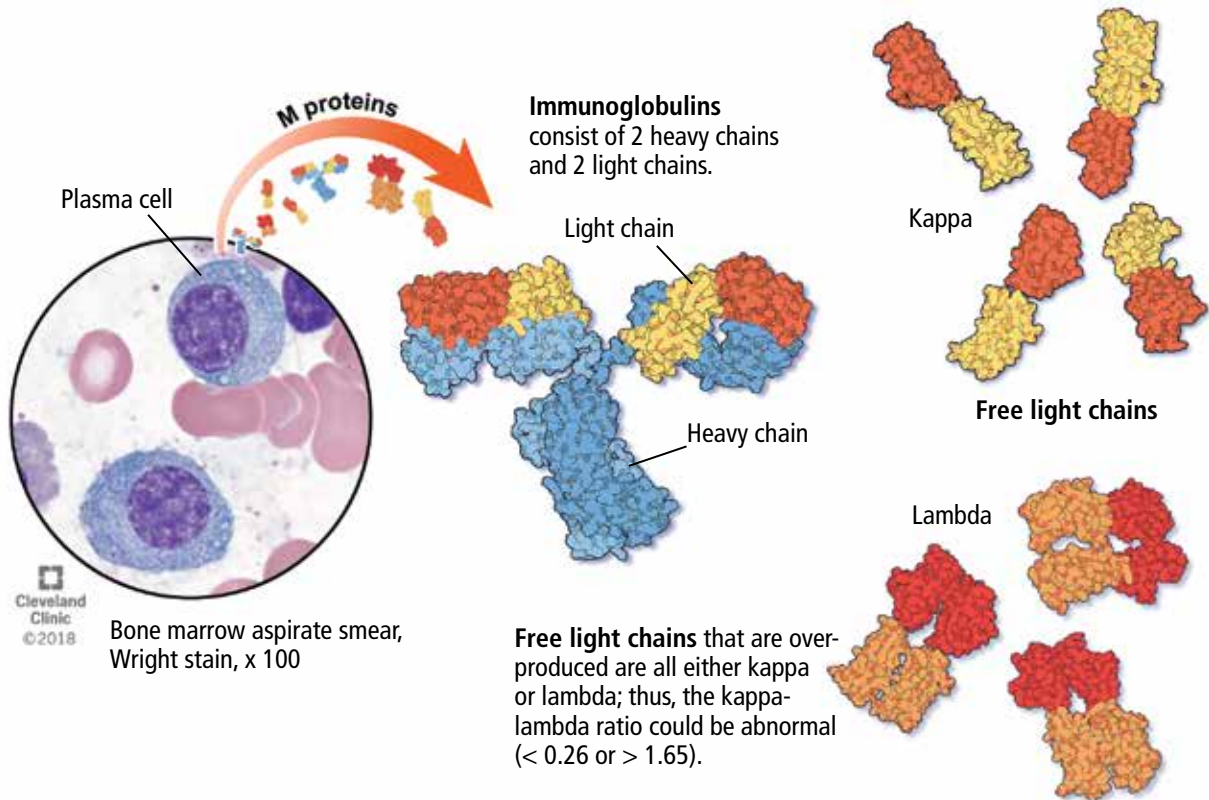
A low anion gap is not a major indicator of an M protein unless in a high concentration, in which case other manifestations would be present, such as renal failure, which would guide the diagnosis. Polyclonal hypergammaglobulinemia as a cause of low anion gap is far more common than MGUS.

**■ HOW SHOULD WE SCREEN FOR AN M PROTEIN?**

**Serum protein electrophoresis** is an initial test used to identify an M protein and has a key role in quantifying it (Figure 2). An M protein appears as a narrow spike on the agarose gel and should be distinguished from the broad band seen in polyclonal gammopathies associated with cirrhosis and chronic infectious and inflammatory conditions, among others.<sup>12</sup> A major disadvantage of serum protein electrophoresis is that it cannot detect an M protein in very low concentrations or determine its identity.

**Serum immunofixation** is more sensitive than serum protein electrophoresis and should always be ordered in conjunction with

Monoclonal gammopathies begin with uncontrolled division of a single plasma cell, leading to abnormal production of monoclonal (M) proteins, consisting of an antibody (immunoglobulin) or free light chain.



**Figure 1.**

it, mostly to ensure detecting tiny amounts of M protein and to identify the type of its heavy chain and light-chain components.<sup>13</sup>

The serum free light-chain assay is also considered an essential part of the screening process to detect light-chain MGUS and light-chain myeloma. As many as 16% of myeloma patients secrete only light chains, which may not be identified on serum immunofixation.<sup>3,6,7,10,14,15</sup> In general, a low kappa-lambda ratio ( $< 0.26$ ) indicates the overproduction of lambda light chains, and a high ratio ( $> 1.65$ ) indicates the overproduction of kappa light chains.

The serum free light-chain assay helps detect abnormal secretion of monoclonal light chains before they appear in the urine once the kidney tubules become saturated and unable to reabsorb them.

Of note, the free light-chain ratio can be abnormal ( $< 0.26$  or  $> 1.65$ ) in chronic kidney

disease. Thus, it may be challenging to discern whether an abnormal light-chain ratio is related to impaired light-chain clearance by the kidneys or to MGUS. In general, kappa light chains are more elevated than lambda light chains in chronic kidney disease, but the ratio should not be considerably skewed. A kappa-lambda ratio below 0.37 or above 3 is rarely seen in chronic kidney disease and should prompt workup for MGUS.<sup>16</sup>

**Tests in combination.** The sensitivity of screening for M proteins ranges from 82% with serum protein electrophoresis alone to 93% with the addition of serum immunofixation and to 98% with the serum free light-chain assay.<sup>15</sup> The latter can replace urine protein electrophoresis and immunofixation when screening for M protein, given its higher sensitivity.<sup>15,17</sup> An important caveat is that urine dipstick testing does not detect urine light chains.

Once an M protein is found, immuno-

TABLE 2

## Indications for testing for monoclonal gammopathy

### Symptoms and signs

Peripheral neuropathy (demyelinating or axonal) with or without autonomic features

Pathologic fractures

Raynaud phenomenon, acrocyanosis (suggestive of cryoglobulinemia)

Hyperviscosity symptoms (headaches, blurry vision, lightheadedness, shortness of breath) in the presence of an immunoglobulin M monoclonal protein

Heart failure symptoms of unclear etiology with findings on ultrasonography suggestive of cardiac amyloidosis

Unexplained peripheral edema: a key caveat is nephrotic syndrome, in which testing for light-chain amyloidosis should be considered

### Laboratory and imaging findings

Normocytic anemia of unclear etiology

High erythrocyte sedimentation rate

Elevated serum viscosity

Elevated total serum protein

Nephrotic-range proteinuria

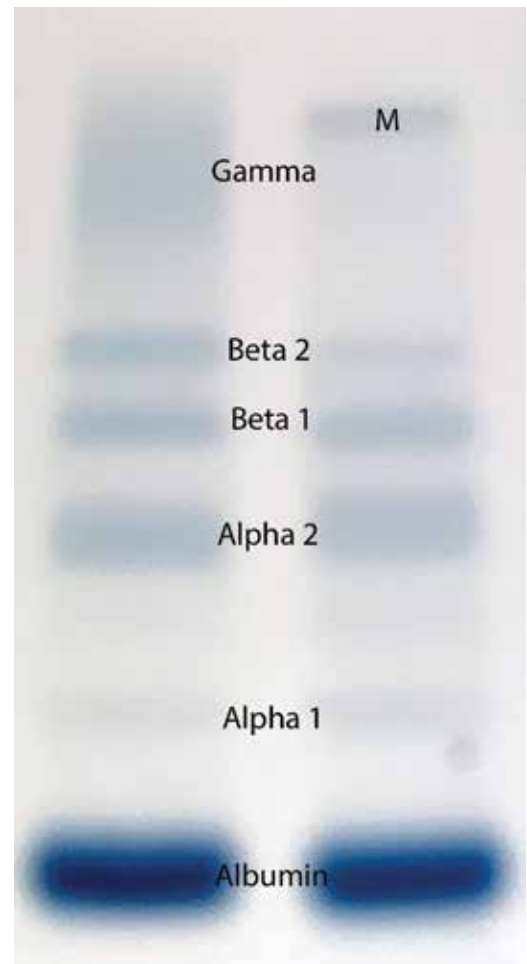
Unexplained renal failure

Elevated calcium level

Osteolytic lesions on imaging

Recurrent infections (mostly sinopulmonary)

Hypo- or hypergammaglobulinemia



**Figure 2.** Serum protein electrophoresis from a patient with monoclonal gammopathy of undetermined significance (right) shows an abnormal band of gamma globulin (labeled M) that is not present in a normal study (left).

globulin quantification, a complete blood cell count, and serum creatinine and calcium measurements are also recommended to look for anemia, renal failure, and hypercalcemia, which can be associated with symptomatic myeloma.<sup>3,5,6,18–22</sup>

Table 3 lists the initial laboratory tests required in patients with MGUS.

## WHAT IS THE DIFFERENTIAL DIAGNOSIS OF MONOCLONAL GAMMOPATHIES?

MGUS should be differentiated from other plasma-cell and lymphoproliferative disorders that feature an M protein and would otherwise require treatment (Table 4). The differential

diagnosis includes smoldering multiple myeloma, symptomatic multiple myeloma, Waldenström macroglobulinemia, light-chain amyloidosis, low-grade B-cell lymphoproliferative disorders, a variety of monoclonal protein-related kidney disorders, and plasmacytomas.<sup>10,14</sup>

## MGUS

Based on the International Myeloma Working Group consensus, a formal diagnosis of MGUS is established when a serum M protein is detected and measured at a concentration less than 3 g/dL on serum protein electrophoresis along with less than 10% clonal plasma cells in the bone marrow.<sup>1–6,14,18,19</sup> Nev-

TABLE 3

**Initial laboratory tests in MGUS**

Complete blood cell count
Serum calcium level
Serum creatinine level
Serum free light chains
Serum immunofixation
24-hour urine protein electrophoresis
Immunoglobulin quantification

MGUS = monoclonal gammopathy of undetermined significance

ertheless, bone marrow biopsy can be omitted in certain patients as discussed below. The absence of myeloma-related organ damage—particularly osteolytic bone lesions, anemia, otherwise unexplained renal failure, and hypercalcemia—is fundamental and necessary for a diagnosis of MGUS.

**Smoldering multiple myeloma**

Compared with patients with MGUS, patients with smoldering multiple myeloma have higher M protein concentrations ( $\geq 3$  g/dL) or 10% or more clonal plasma cells in the marrow or both, and are at higher risk of progression to symptomatic multiple myeloma. Nevertheless, like patients with MGUS, they have no myeloma symptoms or evidence of end-organ damage.

**Symptomatic multiple myeloma**

By definition, patients with multiple myeloma develop organ damage related to their malignancy and need therapy to halt disease progression. Multiple myeloma causes clinical manifestations through cellular infiltration of the bone and bone marrow (anemia, osteolysis, and hypercalcemia) and light chain-induced toxicity (renal tubular damage and cast nephropathy).

In 2014, the definition of multiple myeloma was updated to include 3 new myeloma-defining events that herald a significantly higher risk of progression from smoldering to symptomatic multiple myeloma, and now constitute an integral part of the diagnosis of symptomatic multiple myeloma. These are:

- Focal lesions ( $> 1$  lesion larger than 5 mm)

TABLE 4

**Monoclonal gammopathy: Differential diagnosis**

Monoclonal gammopathy of undetermined significance (MGUS)
Smoldering multiple myeloma
Multiple myeloma
Light-chain amyloidosis
Waldenström macroglobulinemia
POEMS syndrome (polyneuropathy, organomegaly, endocrinopathy, M protein, and skin changes/sclerotic bone lesions, usually lambda)
Plasmacytoma (solitary or multiple, medullary or extramedullary)
Miscellaneous MGUS-related disorders:
Monoclonal gammopathy of renal significance (including light-chain deposition disease, usually kappa type), Fanconi syndrome, and light-chain amyloidosis
Immunoglobulin M-related neuropathy, and anti-myelin-associated glycoprotein antibody neuropathy
Cryoglobulinemia

- visible on magnetic resonance imaging
- $\geq 60\%$  clonal plasma cells on bone marrow biopsy
- Ratio of involved to uninvolved serum free light chains  $\geq 100$  (the involved light chain is the one detected on serum protein electrophoresis and immunofixation).<sup>14</sup>

Bone pain, symptoms of anemia, and decreased urine output may suggest myeloma, but are not diagnostic. Although the “CRAB” criteria (elevated calcium, renal failure, anemia, and bone lesions) define multiple myeloma, the presence of anemia, hypercalcemia, or renal dysfunction do not by themselves mark transformation from MGUS to multiple myeloma. Thus, other causes need to be considered, since the risk of transformation is so low. Importantly, hyperparathyroidism must be ruled out if hypercalcemia is present in a patient with MGUS.<sup>10</sup>

**Waldenström macroglobulinemia**

Waldenström macroglobulinemia, also called lymphoplasmacytic lymphoma, is an indolent non-Hodgkin B-cell lymphoma that can invade the marrow, liver, spleen, and lymph nodes, leading to anemia and organomegaly. It features a monoclonal IgM protein that can be

**An M protein is typically found incidentally**



TABLE 5

### Risk factors for progression in MGUS

#### Risk factors

Non-immunoglobulin G-type M protein

M protein concentration  $\geq 1.5$  g/dL

Abnormal serum free light chain ratio

#### Risk category

Low risk: All 3 risk factors absent

Low intermediate: 1 risk factor present

High intermediate: 2 risk factors present

High risk: All 3 risk factors present

associated with increased blood viscosity, cold agglutinin disease, peripheral neuropathy, and cryoglobulinemia.

Waldenström macroglobulinemia should be suspected in any patient with IgM type M protein and symptoms related to hyperviscosity (headache, blurry vision, lightheadedness, shortness of breath, unexplained epistaxis, gum bleeding); systemic symptoms (fever, weight loss, and night sweats); and abdominal pain (due to organomegaly).<sup>23</sup>

### Monoclonal gammopathy of renal significance

Monoclonal gammopathy of renal significance (MGRS) is a newly recognized entity defined by kidney dysfunction associated with an M protein without evidence of myeloma or other lymphoid disorders.<sup>24</sup> Multiple disorders have been included in this category with different underlying mechanisms of kidney injury. This entity is beyond the scope of this discussion.

### Light-chain amyloidosis

Misfolded light-chain deposition leading to organ dysfunction is the hallmark of light-chain amyloidosis, which constitutes a subset of MGRS. An abnormal light-chain ratio, especially if skewed toward lambda should trigger an investigation for light-chain amyloidosis.<sup>10</sup>

Abnormal light chains may infiltrate any organ or tissue, but of greatest concern is infiltration of the myocardium with ensuing heart failure manifestations. N-terminal pro-B-type

natriuretic peptide (NT-proBNP) is a sensitive marker for cardiac amyloidosis in the presence of suggestive features on transthoracic echocardiography (eg, left ventricular hypertrophy) but is not specific as it can be elevated in heart failure regardless of the underlying cause.<sup>10</sup>

Glomerular injury with nephrotic syndrome may also point toward renal involvement by light-chain amyloidosis and establishes a key distinctive factor from myeloma in which tubular injury is the main mechanism of kidney dysfunction.

Clinical clues for light-chain amyloidosis include heart failure symptoms, neuropathy, and macroglossia. If any of these symptoms and signs is present, we recommend electrocardiography (look for low voltage in limb leads), transthoracic echocardiography, measuring the NT-proBNP level, and urinalysis to look for albuminuria. Notably, carpal tunnel syndrome may be a very early clinical manifestation of amyloidosis, but by itself it is non-specific. Light-chain amyloidosis is a common cause of macroglossia in adults.<sup>10,25</sup>

Neuropathy associated with M proteins is a clinical entity related to a multitude of disorders that may necessitate treating the underlying cellular clone responsible for the secretion of the toxic M protein. These disorders include light-chain amyloidosis, POEMS (polyneuropathy, organomegaly, endocrinopathy, M protein, and skin changes or sclerotic bone lesions) syndrome, and IgM-related neuropathies with anti-myelin-associated glycoprotein antibodies.<sup>3,10,11,14</sup>

Notably, weight loss and fatigue in a patient with MGUS may be the first signs of light-chain amyloidosis or Waldenström macroglobulinemia and should prompt further evaluation.<sup>25</sup>

### HOW ARE PATIENTS WITH MGUS RISK-STRATIFIED AND FOLLOWED?

Research has helped to refine the diagnostic workup and recognize subsets of patients with MGUS at different risks of progression to myeloma and related disorders. Factors predicting progression are<sup>1,6,7,26,27</sup>:

- The amount of the M protein
- The type of M protein (IgG vs non-IgG)
- An abnormal free light-chain ratio.

Based on these predictors, MGUS can be

**Hyperparathyroidism must be ruled out if hypercalcemia is present in a patient with MGUS**

classified into 4 risk categories: low, low-intermediate, high-intermediate, and high (Table 5).

Half of patients with MGUS fall into the low-risk category, which is defined by IgG-type serum M protein in a concentration less than 1.5 g/dL and a normal serum free light-chain ratio (kappa-lambda 0.26–1.65).<sup>5,27</sup> The absolute risk of progression at 20 years is only 5% for patients with low-risk MGUS, compared with 58% in patients with high-risk MGUS (positive for all 3 risk factors).<sup>5</sup>

The presence of less than 10% plasma cells in the bone marrow is required to satisfy the definition of MGUS, but bone marrow biopsy can be omitted for patients with low-risk MGUS, given the slim chance of finding a significant percentage of clonal plasma cells in the marrow and the inherently low risk of progression.<sup>5,10</sup> Skeletal surveys are often deferred for low-risk MGUS, but we obtain them in all our patients to ensure the absence of plasmacytomas, which need to be treated (typically with radiotherapy). Importantly, patients with unexplained bone pain (mostly in long bones, ribs, and spine, whereas joints are not typically involved) and a normal skeletal survey should undergo advanced imaging (whole-body magnetic resonance imaging or whole-body positron emission tomography and computed tomography) to detect bone lesions otherwise missed on plain radiography.<sup>28,29</sup>

Most of the recommendations regarding follow-up are based on expert opinion, given the lack of randomized data. Most experts agree that all patients should be reevaluated 6 months after an M protein is detected, with laboratory surveillance tests (complete blood cell count, serum creatinine, serum calcium level, serum protein electrophoresis, and serum free light chains). Low-risk patients with a stable M protein level can be followed every 2 to 3 years.

Suspect malignant progression if the serum M protein level increases by 50% or more (with an absolute increase of  $\geq 0.5$  g/dL); the serum M protein level is 3 g/dL or higher; the serum free light-chain ratio is more than 100; or the patient has unexplained anemia, elevated creatinine, bone pain, fracture, or hypercalcemia.

Patients at intermediate or high risk should be followed annually after the initial 6-month visit.<sup>5,7,10</sup>

**TABLE 6**

### **MGUS: When to refer patients to a hematologist**

Intermediate- and high-risk MGUS

Suspicion of multiple myeloma or other concomitant malignancy

Suspicion of light chain amyloidosis (including abnormal serum free light chain ratio), for help with diagnostic workup

Possible MGUS-related disorders (peripheral neuropathy, monoclonal gammopathy of renal significance)

MGUS = monoclonal gammopathy of undetermined significance

A recent study highlighted the importance of risk stratification in reducing the costs associated with an overzealous diagnostic workup of patients with low-risk MGUS.<sup>30</sup> These savings are in addition to a reduction in patient anticipation and anxiety that universally occur before invasive procedures.

### **THE ROLE OF THE PRIMARY CARE PROVIDER AND THE HEMATOLOGIST**

Once an M protein is identified, a comprehensive history, physical examination, and laboratory tests (serum protein electrophoresis to quantify the protein, serum immunofixation, serum free light chains, complete blood cell count, calcium, and creatinine) should be done, taking into consideration the differential diagnosis of monoclonal gammopathies discussed above. After MGUS is confirmed, the patient should be risk-stratified to determine the need for bone marrow biopsy and to predict the risk of progression to more serious conditions.

Referral to a hematologist is warranted for patients with intermediate- and high-risk MGUS, patients with abnormal serum free light-chain ratios, and those who show evidence of malignant progression. Patients with intermediate- and high-risk MGUS could be referred for bone marrow biopsy before assessment by a hematologist. The primary care provider may continue to follow patients with low-risk MGUS who do not display clinical or laboratory evidence of myeloma or related disorders.

When light-chain amyloidosis, Waldenström macroglobulinemia, or another M protein-related disorder is suspected, referral to subspecialists is advised to better define the correlation between the M protein and the pa-

**Light-chain amyloidosis is a common cause of macroglossia in adults**

tient's symptoms and signs (Table 6).

The importance of educating patients to report any new worrisome symptom (eg, fatigue, neuropathy,

weight loss, night sweats, bone pain) cannot be over-emphasized, as some patients may progress to myeloma or other disorders between follow-up visits. ■

## REFERENCES

1. van de Donk NW, Palumbo A, Johnsen HE, et al; European Myeloma Network. The clinical relevance and management of monoclonal gammopathy of undetermined significance and related disorders: recommendations from the European Myeloma Network. *Haematologica* 2014; 99(6):984–996. doi:10.3324/haematol.2013.100552
2. International Myeloma Working Group. Criteria for the classification of monoclonal gammopathies, multiple myeloma and related disorders: a report of the International Myeloma Working Group. *Br J Haematol* 2003; 121(5):749–757. PMID:12780789
3. Rajan AM, Rajkumar SV. Diagnostic evaluation of monoclonal gammopathy of undetermined significance. *Eur J Haematol* 2013; 91(6):561–562. doi:10.1111/ejh.12198
4. Kyle RA, Rajkumar SV. Monoclonal gammopathy of undetermined significance. *Br J Haematol* 2006; 134(6):573–589. doi:10.1111/j.1365-2141.2006.06235.x
5. Kyle RA, Durie BG, Rajkumar SV, et al; International Myeloma Working Group. Monoclonal gammopathy of undetermined significance (MGUS) and smoldering (asymptomatic) multiple myeloma: IMWG consensus perspectives risk factors for progression and guidelines for monitoring and management. *Leukemia* 2010; 24(6):1121–1127. doi:10.1038/leu.2010.60
6. Bird J, Behrens J, Westin J, et al; Haemato-oncology Task Force of the British Committee for Standards in Haematology, UK Myeloma Forum and Nordic Myeloma Study Group. UK Myeloma Forum (UKMF) and Nordic Myeloma Study Group (NMSG): guidelines for the investigation of newly detected M-proteins and the management of monoclonal gammopathy of undetermined significance (MGUS). *Br J Haematol* 2009; 147(1):22–42. doi:10.1111/j.1365-2141.2009.07807.x
7. Rajkumar SV, Kyle RA, Buadi FK. Advances in the diagnosis, classification, risk stratification, and management of monoclonal gammopathy of undetermined significance: implications for recategorizing disease entities in the presence of evolving scientific evidence. *Mayo Clin Proc* 2010; 85(10):945–948. doi:10.4065/mcp.2010.0520
8. Kyle RA, Therneau TM, Rajkumar SV, et al. A long-term study of prognosis in monoclonal gammopathy of undetermined significance. *N Engl J Med* 2002; 346(8):564–569. doi:10.1056/NEJMoa01133202
9. Doyle LM, Gundrum JD, Farnen JP, Wright LJ, Kranig JAI, Go RS. Determining why and which clinicians order serum protein electrophoresis (SPEP), subsequent diagnoses based on indications, and clinical significance of routine follow-up: a study of patients with monoclonal gammopathy of undetermined significance (MGUS). *Blood* 2009; 114(22):Abstr 4883. www.bloodjournal.org/content/114/22/4883. Accessed December 4, 2018.
10. Merlini G, Palladini G. Differential diagnosis of monoclonal gammopathy of undetermined significance. *Hematology Am Soc Hematol Educ Program* 2012; 2012:595–603. doi:10.1182/asheducation-2012.1.595
11. Glavey SV, Leung N. Monoclonal gammopathy: the good, the bad and the ugly. *Blood Rev* 2016; 30(3):223–231. doi:10.1016/j.blre.2015.12.001
12. Dispenzieri A, Gertz MA, Therneau TM, Kyle RA. Retrospective cohort study of 148 patients with polyclonal gammopathy. *Mayo Clin Proc* 2001; 76(5):476–487. doi:10.4065/76.5.476
13. Merlini G, Stone MJ. Dangerous small B-cell clones. *Blood* 2006; 108(8):2520–2530. doi:10.1182/blood-2006-03-001164
14. Rajkumar SV, Dimopoulos MA, Palumbo A, et al. International Myeloma Working Group updated criteria for the diagnosis of multiple myeloma. *Lancet Oncol* 2014; 15(12):e538–e548. doi:10.1016/S1470-2045(14)70442-5
15. Kyle RA, Gertz MA, Witzig TE, et al. Review of 1027 patients with newly diagnosed multiple myeloma. *Mayo Clin Proc* 2003; 78(1):21–33. doi:10.4065/78.1.21
16. Hutchison CA, Harding S, Hewins P, et al. Quantitative assessment of serum and urinary polyclonal free light chains in patients with chronic kidney disease. *Clin J Am Soc Nephrol* 2008; 3(6):1684–1690. doi:10.2215/CJN.02290508
17. Katzmann JA, Dispenzieri A, Kyle RA, et al. Elimination of the need for urine studies in the screening algorithm for monoclonal gammopathies by using serum immunofixation and free light chain assays. *Mayo Clin Proc* 2006; 81(12):1575–1578. doi:10.4065/81.12.1575
18. Berenson JR, Anderson KC, Audell RA, et al. Monoclonal gammopathy of undetermined significance: a consensus statement. *Br J Haematol* 2010; 150(1):28–38. doi:10.1111/j.1365-2141.2010.08207.x
19. Mangiacavalli S, Cocito F, Pochintesta L, et al. Monoclonal gammopathy of undetermined significance: a new proposal of workup. *Eur J Haematol* 2013; 91(4):356–360. doi:10.1111/ejh.12172
20. Bianchi G, Kyle RA, Colby CL, et al. Impact of optimal follow-up of monoclonal gammopathy of undetermined significance on early diagnosis and prevention of myeloma-related complications. *Blood* 2010; 116:2019–2025. doi:10.1182/blood-2010-04-277566
21. Rosiñol L, Cibeira MT, Montoto S, et al. Monoclonal gammopathy of undetermined significance: predictors of malignant transformation and recognition of an evolving type characterized by a progressive increase in M protein size. *Mayo Clin Proc* 2007; 82(4):428–434. doi:10.4065/82.4.428
22. Vanderschueren S, Mylle M, Dierickx D, et al. Monoclonal gammopathy of undetermined significance: significant beyond hematology. *Mayo Clin Proc* 2009; 84(9):842–845. doi:10.1016/S0025-6196(11)60495-3
23. Kyle RA, Rajkumar SV. Monoclonal gammopathy of undetermined significance and smoldering multiple myeloma: emphasis on risk factors for progression. *Br J Haematol* 2007; 139(5):730–743. doi:10.1111/j.1365-2141.2007.06873.x
24. Leung N, Bridoux F, Hutchison CA, et al; International Kidney and Monoclonal Gammopathy Research Group. Monoclonal gammopathy of renal significance: when MGUS is no longer undetermined or insignificant. *Blood*. 2012; 120(22):4292–4295. doi:10.1182/blood-2012-07-445304
25. Merlini G, Wechalekar AD, Palladini G. Systemic light chain amyloidosis: an update for treating physicians. *Blood* 2013; 121(26):5124–5130. doi:10.1182/blood-2013-01-453001
26. Dispenzieri A, Katzmann JA, Kyle RA, et al. Prevalence and risk of progression of light-chain monoclonal gammopathy of undetermined significance: a retrospective population-based cohort study. *Lancet* 2010; 375(9727):1721–1728. doi:10.1016/S0140-6736(10)60482-5
27. Rajkumar SV, Kyle RA, Therneau TM, et al. Serum free light chain ratio is an independent risk factor for progression in monoclonal gammopathy of undetermined significance. *Blood* 2005; 106(3):812–817. doi:10.1182/blood-2005-03-1038
28. Dimopoulos MA, Hillengass J, Usmani S, et al. Role of magnetic resonance imaging in the management of patients with multiple myeloma: a consensus statement. *J Clin Oncol* 2015; 33(6):657–664. doi:10.1200/JCO.2014.57.9961
29. Dimopoulos M, Kyle R, Fermand JP, et al. Consensus recommendations for standard investigative workup: report of the International Myeloma Workshop Consensus Panel 3. *Blood* 2011; 117(18):4701–4705. doi:10.1182/blood-2010-10-299529
30. Pompa T, Maddox M, Woodard A, et al. Cost effectiveness in low risk MGUS patients. *Blood* 2016; 128:2360. www.bloodjournal.org/content/128/22/2360. Accessed December 4, 2018.

ADDRESS: Jack Khouri, MD, Department of Hematology and Medical Oncology, Taussig Cancer Institute, CA-60, Cleveland Clinic, 10201 Carnegie Avenue, Cleveland, OH 44195; khourij@ccf.org