

TABLE OF CONTENTS

FROM THE EDITOR

A few pearls can help prepare the mind **638**

The caregiver with a prepared mind is more likely to experience the diagnostic epiphany.

B.F. MANDELL

THE CLINICAL PICTURE

Vulvar and gluteal manifestations of Crohn disease **645**

Crohn disease is associated with extraintestinal manifestations in up to 45% of patients.

A.C. MORENO, O. GOJE, M.P. PILIANG, AND P. BATUR

THE CLINICAL PICTURE

A complication of enoxaparin injection **648**

Computed tomography revealed a hematoma measuring 15 by 15 cm compressing the bladder and causing hydronephrosis.

A.M. SHARAYAH, S. ZAIGHAM, N. HAJJAJ, AND M. MANIAR

1-MINUTE CONSULT

What are the risks to inpatients during hospital construction or renovation? **650**

Risks include mold infection, Legionnaires disease, sleep deprivation, exacerbation of lung disease, and physical injury.

A. KANJ, Y. GAO, AND A.O. SOUBANI

1-MINUTE CONSULT

Does my patient need maintenance fluids? **653**

The question seems like it should have an easy answer. However, there is no consensus.

J. SANCHEZ AND R. LICHTENBERG

CONTINUED ON PAGE 636



Online Features

Access

Cleveland Clinic Journal of Medicine content is readily available to all and is free of charge at www.ccjm.org.

Services

- Navigate quickly to articles in current and past issues via links on the home page and pull-down menus at the top of the page. Use the search function to find a specific article, or browse by topic or article type.
- Continuing medical education and maintenance of certification activities are accessible from article links and from a CME pull-down menu on the home page. Participation is free.
- Follow links on the home page to news, summaries of recent scientific meetings, and interactive quizzes.
- Click on the PDF symbol at the top of any online article to read, download, or print the article in PDF format.

Social Networking

To post a *CCJM* article to Facebook or Twitter, just click on the icon at the top of any online article.

www.ccjm.org

CONTINUED FROM PAGE 634

MEDICAL GRAND ROUNDS

Myopathy for the general internist: Statins and much more 656

How to evaluate and manage muscle complaints in patients taking a statin, interpret creatine kinase test results, and recognize common as well as potentially dangerous myopathies.

C.V. ODDIS

SYMPTOMS TO DIAGNOSIS 

A 66-year-old man with abnormal thyroid function tests 666

A 66-year-old man presents with an acute exacerbation of COPD requiring hospitalization.

Y.N. ALHALASEH, Z.A. ABDULELAH, A.O. ARMOUTI, AND A.A. ZAYED

REVIEW 

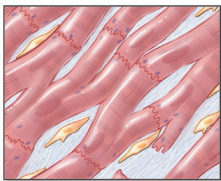
2019 Update in perioperative cardiovascular medicine 677

Studies of preoperative cardiac risk assessment, perioperative medication management, and postoperative complications.

S.L. COHN, P.J. GRANT, AND B. SLAWSKI

REVIEW 

Cardiovascular complications of systemic sclerosis: What to look for 685



Pulmonary arterial hypertension, atherosclerosis, heart failure, arrhythmias, pericardial disease, and valvular heart disease.

P. MANI, D. GONZALEZ, S. CHATTERJEE, AND M.D. FAULX

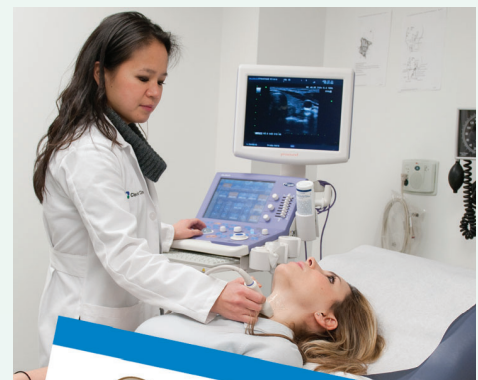DEPARTMENTS

CME Calendar 647

CME/MOC Instructions Inside back cover

Upcoming Features

- Functional heartburn: The brain-gut connection
- Gabapentin for alcohol use disorder: Opportunity for abuse?
- Barrett esophagus: Treatable cancer precursor
- Cardio-obstetrics: Better maternal outcomes
- Migraine lifestyle hacks
- Familial hypercholesterolemia: Advances, recommendations
- STI update: Testing, treatment, trends
- Fever in a returning traveler
- Sepsis: Guideline-based management



CLEVELAND CLINIC JOURNAL OF MEDICINE