

TABLE OF CONTENTS

FROM THE EDITOR

There is more to the TSH than a number 77

Management of subclinical hypothyroidism should be nuanced and based on clinical and laboratory parameters.

B.F. MANDELL

THE CLINICAL PICTURE.....

Aleukemic leukemia cutis 85

An 85-year-old man presented with rapidly progressive nodules on the scalp, neck, trunk, and extremities.

T.N. ABRAHAM, P. MORAWIECKI, A. FLISCHEL, AND B. AGRAWAL

THE CLINICAL PICTURE.....

Dancing sternal wires: A radiologic sign of sternal dehiscence 87

Loose fragments of bone and wire pose a danger of puncturing the heart, making sternal dehiscence a surgical emergency.

M.M. GAD AND A. GUPTA

1-MINUTE CONSULT

Repeating blood cultures after initial bacteremia: When and how often? 89

Repeating blood cultures after an initial positive result is superfluous except in certain situations.

A. MUSHTAQ, B.X. BREDELL, AND A.O. SOUBANI

EDITORIAL

Follow-up blood cultures are often needed after bacteremia 93

Without follow-up cultures, the adequacy of treatment can be difficult to assess.

M. TUNGSIRIPAT

CONTINUED ON PAGE 76



Online Features

Access

Cleveland Clinic Journal of Medicine content is readily available to all and is free of charge at www.ccjm.org.

Services

- Navigate quickly to articles in current and past issues via links on the home page and pull-down menus at the top of the page. Use the search function to find a specific article, or browse by topic or article type.
- Continuing medical education and maintenance of certification activities are accessible from article links and from a CME pull-down menu on the home page. Participation is free.
- Follow links on the home page to news, summaries of recent scientific meetings, and interactive quizzes.
- Click on the PDF symbol at the top of any online article to read, download, or print the article in PDF format.

Social Networking

To post a *CCJM* article to Facebook or Twitter, just click on the icon at the top of any online article.

www.ccjm.org

CONTINUED FROM PAGE 74

REVIEW **CME MOC** ACCREDITED

Managing malignant pleural effusion 95

Depending on the circumstances, options are observation, thoracentesis, an indwelling catheter, and chemical pleurodesis.

A.S. WAHLA, M. UZBECK, Y. ABU EL SAMEED, AND Z. ZOOMOT

REVIEW **CME MOC** ACCREDITED

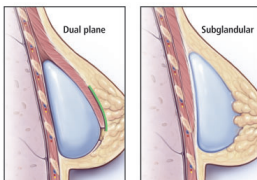
Subclinical hypothyroidism: When to treat 101

The decision remains controversial and depends on the degree of TSH elevation, thyroid antibodies, and comorbidities.

S. AZIM AND C. NASR

REVIEW **CME MOC** ACCREDITED

Breast augmentation surgery: Clinical considerations 111



The evolution of breast implants, their complications, and key considerations with regard to aesthetic breast surgery.

D.M. COOMBS, R. GROVER, A. PRASSINOS, AND R. GURUNLUOGLU

REVIEW **CME MOC** ACCREDITED

Heart failure guidelines: What you need to know about the 2017 focused update 123

Prevention, preserved ejection fraction, hypertension, iron, sleep apnea, and acute decompensation.

L.R. HASELHUHN, D.J. BROTMAN, AND I.S. WITTSTEIN

DEPARTMENTS

From the *Cleveland Clinic Journal of Medicine* 79

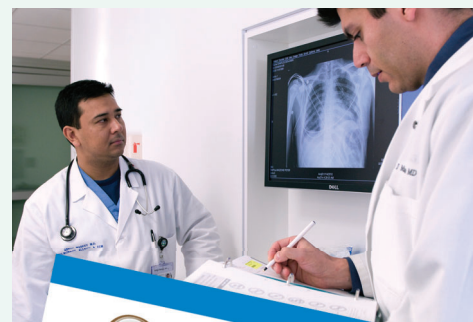CME Calendar 79

Our peer-reviewers for 2018 140

CME/MOC Instructions 141

Upcoming Features

- Papillomavirus update: Defeating cervical cancer
- Detecting fibrosis in hepatitis C and fatty liver disease
- Postural tachycardia: Evaluation and management
- Neglected numbers on the CBC
- Smart imaging for syncope
- Type 2 diabetes: Toward precision care
- Spontaneous coronary artery dissection
- Acute kidney injury after arthroplasty
- Sleep apnea after stroke
- Cancer screening: The benefit and the harm



CLEVELAND CLINIC JOURNAL OF MEDICINE