

DEMETRIUS M. COOMBS, MDDepartment of Plastic Surgery,
Dermatology and Plastic Surgery Institute,
Cleveland Clinic**RITWIK GROVER, MD**Department of Plastic Surgery,
Dermatology and Plastic Surgery
Institute, Cleveland Clinic**ALEXANDRE PRASSINOS, MD**Division of Plastic and Reconstructive
Surgery, Department of Surgery,
Yale School of Medicine, New Haven, CT**RAFFI GURUNLUOGLU, MD, PhD**Department of Plastic Surgery, Dermatology and
Plastic Surgery Institute, Cleveland Clinic; Profes-
sor, Cleveland Clinic Lerner College of Medicine of
Case Western Reserve University, Cleveland, OH

Breast augmentation surgery: Clinical considerations

ABSTRACT

Women receive breast implants for both aesthetic and reconstructive reasons. This brief review discusses the evolution of and complications related to breast implants, as well as key considerations with regard to aesthetic and reconstructive surgery of the breast.

KEY POINTS

Nearly 300,000 breast augmentation surgeries are performed annually, making this the second most common aesthetic procedure in US women (after liposuction).

Today, silicone gel implants dominate the world market, and in the United States, approximately 60% of implants contain silicone gel filler.

Capsular contracture is the most common complication of breast augmentation, typically presenting within the first postoperative year and with increasing risk over time. It occurs with both silicone and saline breast implants.

Numerous studies have demonstrated the safety of silicone breast implants with regard to autoimmune disease incidence. However, the risk of associated anaplastic large-cell lymphoma must be discussed at every consultation, and confirmed cases should be reported to a national registry.

AT PRESENT, 300,000 US women undergo breast augmentation surgery each year,¹ making this the second most common aesthetic procedure in women (after liposuction),²⁻⁴ and making it extremely likely that clinicians will encounter women who have breast implants. In addition, approximately 110,000 women undergo breast reconstructive surgery after mastectomy, of whom more than 88,000 (81%) receive implants (2016 data).⁵

This review discusses the evolution of breast implants, their complications, and key considerations with regard to aesthetic and reconstructive breast surgery, as the principles are similar.

EVOLUTION OF IMPLANTS

Reports of breast augmentation surgery, also known as augmentation mammoplasty, date back to 1895, when a fatty tumor (lipoma) was successfully transplanted from a patient's back to a breast defect in a mastectomy patient.^{2,3,6,7} In the 1930s, implantation of a glass ball into a patient's breast marked the first implant-based breast augmentation.⁶ By 1954, attempts at breast augmentation using local dermal-fat flaps, adipose tissue, and even omentum were described.

Alloplastic materials gained popularity throughout the 1950s and 1960s and included polyurethane, polytetrafluoroethylene (Teflon), and other synthetics. Adverse reactions associated with alloplastic materials were plentiful: local tissue reactions, distortion of the breast mound, increased firmness, and discomfort all contributed to the eventual discontinuation of their use. The history of alloplastic breast augmentation also included

doi:10.3949/ccjm.86a.18017

TABLE 1

Silicone breast implants by generation**First generation (1960s)**

Shell	Thick, smooth, silicone elastomer in 2 pieces with Dacron patches posteriorly to facilitate positioning along the chest wall
Filler	Silicone gel, moderate viscosity
Shape	Anatomic or “teardrop”
Complications	High capsular contracture rate (approached 100% at 10 years after implantation)

Second generation (1970s)^a

Shell	Thinner, smooth, seamless, no Dacron patches
Filler	Silicone gel, thinner and less viscous
Shape	Round
Complications	Rupture (nearly 60%), diffusion or “bleeding” of silicone molecules into periprosthetic space and onto breast implant capsule

Third generation (1980s)^b

Shell	Thicker, multilayer silicone elastomer, no Dacron patches
Filler	Silicone gel with larger particles, increased cross-linking, more viscous and thick

Fourth and fifth generation (1990s to present)^c

Shell and filler	Shell thickness and gel viscosity redesigned according to strict criteria by American Society for Testing Methodology and US Food and Drug Administration
Shape	Anatomic (teardrop)

^a During this period subpectoral implant placement gained popularity, decreasing capsular contracture rates.

^b Restricted from US market temporarily in 1992; textured surfaces were introduced during this period in an effort to decrease capsular contracture.

^c Greater quality control during manufacturing; wider variety of implant shapes and surface texturing available.

epoxy resin, shellac, beeswax, paraffin, rubber, petroleum jelly, and liquefied silicone. Outcomes were not good, and many patients ultimately needed mastectomy.⁷

The first modern breast prosthesis was developed in 1961, and since then, implant composition and design have evolved significantly.⁸

From silicone to saline, and back again

The first silicone gel implants, introduced in the early 1960s,^{8–19} had high complication rates—some centers reported an incidence of capsular contracture of up to 70%.^{8,11} This is a foreign body reaction in which pathologic scar tissue encases the implant, causing it to distort, appear misshapen, harden, and even become painful.¹¹ Attempts to minimize this reaction led to later generations of silicone implants with polyurethane shells.¹²

Inflatable implants filled with sterile saline solution were originally developed in France in 1965. Unlike silicone implants, saline implants have undergone minimal changes since their inception, and grew in popularity during the 1970s in view of the high rates of capsular contracture with silicone implants.⁸ However, saline implants have their own problems, and as they became increasingly popular, deflation and the unnatural feel of saline sparked a renewed interest in silicone gel.

By the late 1980s, the thinner-shelled generation of silicone implants displayed its own frustrating complications including implant rupture, capsular contracture, infection, and possible systemic and disseminated granulomatous disease. From 1992 to 2006, the US Food and Drug Administration (FDA) placed a moratorium on silicone implants due to concerns about a possible link with autoimmune and connective tissue diseases and the possible carcinogenic nature of silicone.

While silicone implants were prohibited in the United States, development continued abroad, and eventually the moratorium was lifted after several meta-analyses failed to reveal any link regarding the aforementioned concerns.¹³

Today, silicone gel implants dominate the world market.¹⁴ In the United States, approximately 60% of implants contain silicone gel filler, and trends are similar in Europe.⁷

Table 1 summarizes the evolution of silicone breast implants over the last 50 years.^{2,6,11,12} **Table 2** lists the advantages and disadvantages of silicone and saline breast implants.^{2,6,8,15}

CURRENT IMPLANT OPTIONS

Currently, 3 companies (Allergan, Mentor, Sientra) manufacture and distribute breast implants and implant-associated products

TABLE 2

Advantages and disadvantages of silicone and saline breast implants

	Advantages	Disadvantages
Silicone	<p>Consistency with palpation mimics dense, natural breast tissue</p> <p>Quicker adjustment to alterations in the external environment</p>	<p>Exposure to silicone in the event of rupture, and rupture not immediately evident</p> <p>Higher initial cost (nearly double that of saline implants), including cost of recommended monitoring (imaging) to ensure implant integrity</p>
Saline	<p>Only a small incision is required for implant insertion (implant filled with saline to desired volume through a port)</p> <p>Saline is safely absorbed by the body in the event of rupture, and rupture is immediately evident (breast deflation)</p> <p>No concern for silicone exposure in the event of rupture</p>	<p>Overfilling leads to increased firmness, palpability of the implant edge</p> <p>Underfilling results in rippling and a higher risk of rupture from the shell folding upon itself</p> <p>Consistency with palpation mimics water (as opposed to natural breast tissue)</p> <p>Slow to adjust to alterations in the external environment (eg, feels cold after swimming)</p> <p>Slightly higher rate of rupture</p>

such as tissue expanders and sizers in the US market.⁶

Another company, Motiva, makes an implant that is available in Europe, Asia, and Australia, and the device is currently undergoing a 10-year clinical trial in the United States that began recruiting patients in 16 centers in April 2018.¹⁶ Pending final approval, the Cleveland Clinic Department of Plastic Surgery may be among the centers involved in the clinical trial of the Motiva implant. Innovations in the Motiva implant include a high-performance shell that maintains consistent strength and includes a proprietary barrier layer, improved silicone gel filler, 3-D imprinted surface texturing, and an implant shape that adapts with vertical and horizontal movement. It also contains radio-frequency identification transponders that can transmit data about the implant wirelessly.^{17–19}

Surface (textured vs smooth)

Developed in the 1980s, texturing of the implant surface disrupts capsule formation around the prosthesis. Additionally, texturing stabilizes an anatomically shaped (teardrop) implant within the breast pocket, reducing

malrotation.^{20,21}

The first textured implants were covered with polyurethane foam, but they were ultimately withdrawn from the US market because of concern for in vivo degradation to carcinogenic compounds. The focus subsequently turned to texturing implant shells by mechanically creating pores of different sizes. Smooth implants, by contrast, are manufactured by repeatedly dipping the implant shell into liquid silicone.²

The capsular contraction rate has been shown to be lower with textured silicone than with smooth silicone (number needed to treat = 7–9), and evidence suggests a lower risk of needing a secondary procedure.²¹

Form-stable vs fluid-form

Silicone is a polymer. The physical properties of polymers vary greatly and depend on the length of the individual chains and the degree to which those chains are cross-linked. Liquid silicone contains short chains and sparse cross-linking, resulting in an oily compound well suited for lubrication. Silicone gel contains longer chains and more cross-linking and is therefore more viscous.

An early report of breast augmentation surgery was in 1895

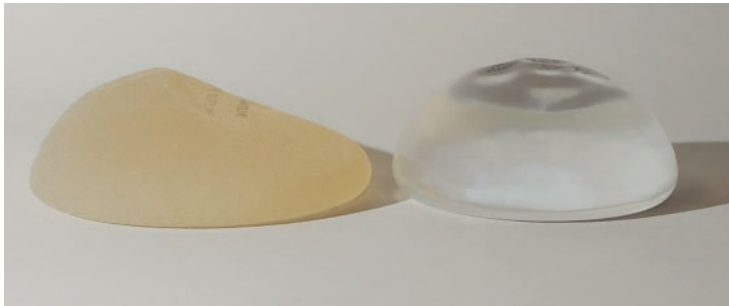


Figure 1. Silicone breast implants. Left, textured and anatomically shaped; right, smooth and round. Note the sloping projection of the anatomic implant. The fuller portion would be oriented inferiorly in the patient to simulate a native breast shape.

In “form-stable” implants, the silicone interior has sufficient chain length and cross-linking to retain the designed shape even at rest,² but they require slightly larger incisions.⁷ “Fluid-form” refers to an implant with silicone filler with shorter chain length, less cross-linking, and more fluidity.⁶

Shell

As with silicone fillers, the properties of silicone implant shells also depend on chain length and cross-linking within the polymer. Silicone elastomer shells (Table 1) contain extensively cross-linked chains that impart a flexible yet rubbery character. Silicone elastomers can also be found in facial implants and tissue expanders.²

Implant shape (round vs anatomic)

The shape of an implant is determined by the gel distribution inside of it. To understand gel distribution and implant shape, one must understand the gel-shell ratio. This ratio increases as cohesivity of the filler increases, and it represents increased bonding of the gel filler to the shell and a preserved implant shape at rest.

The gel-shell ratio varies among manufacturers, and a less-viscous filler may be more prone to rippling or loss of upper pole fullness in some patients. For this reason, careful analysis, patient and implant selection, and discussion of complications remain paramount.²

No anatomically shaped implant is manufactured with a smooth shell, but rather with a textured shell that resists malrotation.^{6,15} However, in the United States, 95% of patients receive round implants.¹⁶

PATIENT ASSESSMENT

Before breast augmentation surgery, the surgeon assesses a number of factors—physical and psychosocial—and helps the patient choose a type and size of implant. The surgeon and patient also plan where the implants will be placed—ie, above or beneath the chest wall muscle—and where the incisions will be made. Every decision is made in close consultation with the patient, taking into account the patient’s desires and expectations, as well as what the patient’s anatomy allows. An integral component of this shared decision-making process is a discussion of the possible complications, and often photographs to better illustrate what to expect postoperatively.

Psychosocial factors

One must consider the patient’s psychology, motivations for surgery, and emotional stability. Here, we look for underlying body dysmorphic disorder; excessive or unusual encouragement to undergo the procedure by a spouse, friends, or others; a history of other aesthetic procedures; unrealistic expectations; and other factors influencing the desire to undergo this surgery.

Choosing an implant

Implant selection must take into account the patient’s height, weight,⁷ and overall body morphology: taller patients and those with wider hips or shoulders usually require larger implants. A reliable method for determining the appropriate implant must include the current breast shape, dimensions, volume, skin elasticity, soft-tissue thickness, and overall body habitus. Ultimately, the most important considerations include breast base diameter, implant volume,²⁰ and soft-tissue envelope.

Filler type, followed by shape (round or anatomically shaped), anterior-posterior profile, and shell type (smooth or textured) are subsequent considerations (Figure 1).

Preoperative sizing can involve placing sample implants within a brassiere so that the patient can preview possible outcomes. This method is particularly effective in minimizing dissatisfaction because it shares ownership of the decision-making process.¹⁵

A computerized implant selection program available in Europe suggests a “best-fit” implant based on a clinician’s measurements.⁷

One must consider the patient’s psychology, motivations for surgery, and emotional stability

Breast augmentation

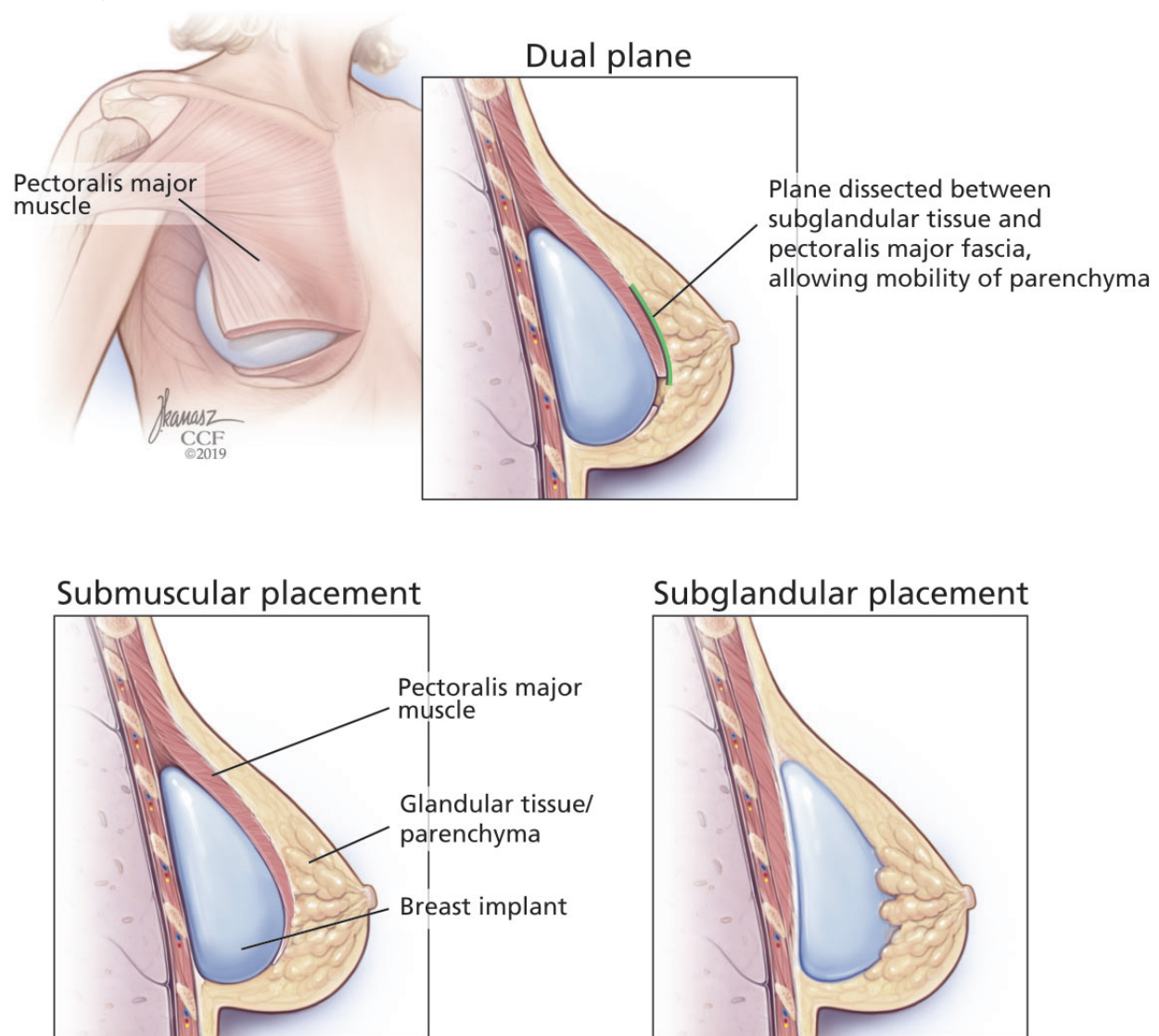


Figure 2. Placement of breast implants.

Anatomic placement

Traditionally, plastic surgeons place breast implants either beneath the pectoralis major muscle (submuscular placement) or over the pectoralis⁸ but beneath the glandular breast parenchyma (subglandular placement) (**Figure 2**).⁷

Advantages of submuscular placement are a smoother transition of the upper breast pole from the chest wall and less rippling visible through the skin, due to the additional muscular coverage of the implant. Another advantage is that capsular contraction rates

are lower with submuscular placement, likely due to possible contamination of implants by lactiferous ductal microbes when accessing the subglandular plane.^{14,20} Disadvantages are pronounced discomfort after surgery and animation deformities with muscle contraction, particularly in young, highly active patients.

A popular modification of submuscular placement involves creating a surgical dissection plane between the subglandular tissue and the pectoralis major fascia. This “dual-plane” approach allows the parenchyma to retract superiorly and reduce breast ptosis.⁷

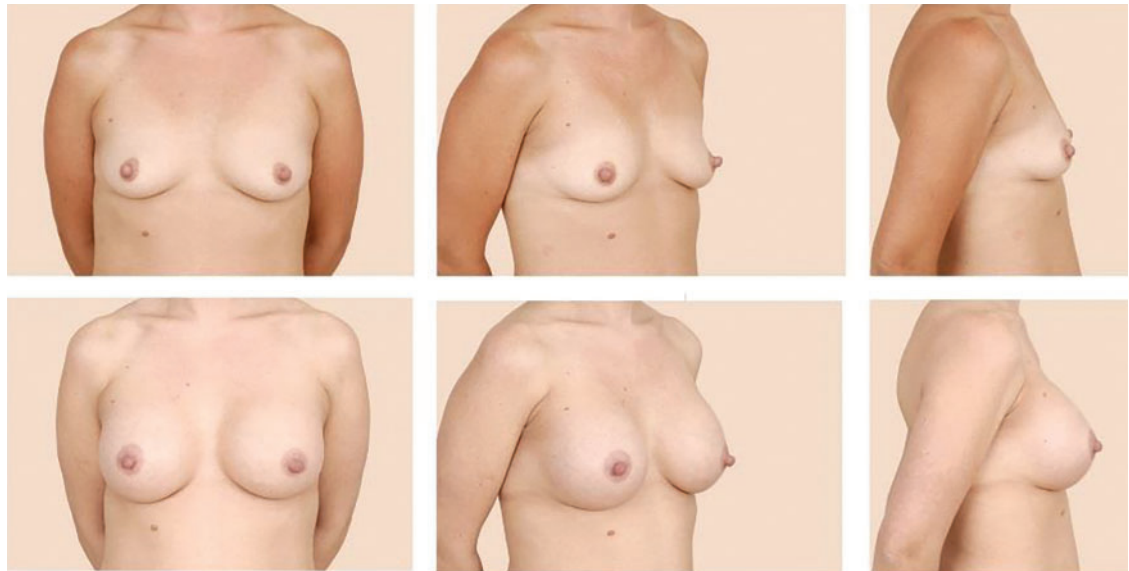


Figure 3. The images in the top row are before breast augmentation. Those in the bottom row are 7 months after breast augmentation surgery with 350-cc smooth, round silicone breast implants placed via an inframammary incision in a subpectoral pocket.

Incisions

The incision is most commonly made along the inframammary fold (**Figure 3**), but it can also be done around the areola, in the axilla, or even through the umbilicus, although this approach is less commonly used.

Table 3 highlights important considerations with regard to incision location.^{15,20,21}

■ ANTIBIOTICS

Many surgeons give a single prophylactic dose of antibiotic before surgery, a practice that some studies have shown to be effective in reducing the risk of infection.¹⁵ However, the benefit of routine postoperative use of antibiotics remains unsubstantiated¹⁵; postoperative antibiotic use does not appear to protect against infection, capsular contracture, or overall complications in primary or secondary breast augmentation surgery.²⁰

■ PERIOPERATIVE PERIOD

At our institution, breast augmentation surgery is an ambulatory procedure—the patient goes home the same day unless circumstances such as pain control warrant admission. This is, however, according to surgeon preference, and differs on a case-by-case basis. General anesthesia is the standard of care.¹⁵

■ POSTOPERATIVE PERIOD

In the immediate postoperative period, patients are instructed to wear a surgical bra for up to 6 weeks to allow stable scarring. Early mobilization is encouraged.^{7,15} Depending on the patient's situation, recovery, and healing, she may be out of work for about 1 week, sometimes more, sometimes less.

Additional instructions are surgeon-specific. However, the patient is instructed to avoid bathing, swimming, immersion in water, and wearing underwire brassieres that could impair healing of an inferior incision; instead, patients are often instructed to wear a surgical bra provided on the day of surgery until cleared in the clinic.

Showering is allowed the next day or the second day after surgery, and of course there is no driving while on narcotics. Additionally, patients are counseled extensively regarding hematoma formation and the signs and symptoms of infection.

Patients are typically seen in clinic 1 week after surgery.

The cost of surgery may be \$5,000 to \$6,000 but can vary significantly from center to center depending on who the patient sees and where, and whether the patient presents for breast reconstruction after cancer or repair

Implant rupture occurs silently in most cases, with no detectable signs or symptoms

TABLE 3

Considerations in incision location

Location	Advantages	Disadvantages
Inframammary	Most common choice Excellent visualization of both the subpectoral and suprapectoral planes of dissection	Visible scar along inferior pole of the breast
Periareolar	Excellent exposure of the implant pocket Less sensory deficit to lower breast pole	Potentially higher rate of capsular contracture Associated with moderate-severe implant malposition and increased risk for secondary procedures Greater propensity for nipple-areola complex dysesthesia Scar located on visible breast surface
Transaxillary	Ideal for saline implants (only require small incisions) Does not affect subsequent sentinel lymph node biopsies High satisfaction rate vs inframmary incisions	Difficult route to place silicone implants Associated with moderate to severe implant malposition and increased risk for secondary procedures
Transumbilical	Remote incision, may be obscured by umbilicus	Less control of implant positioning

of congenital anomalies, or in certain cases of transgender surgery. The patient is typically responsible for the fee, but again this depends on the patient, indications, and particular insurance concerns.

■ IMPLANT LONGEVITY AND RUPTURE

In the United States, implant rupture rates range from 1.1% to 17.7% at 6 to 10 years after primary augmentation, 2.9% to 14.7% after revision augmentation, 1.5% to 35.4% after primary breast reconstruction, and 0% to 19.6% after revision reconstruction.¹¹

Unfortunately, the existence of multiple implant manufacturers, numerous implant generations, and poorly standardized screening protocols and reporting systems make the true rate of implant rupture difficult to assess without definitive imaging or implant retrieval.¹¹

Damage from surgical instrumentation during implantation is the most common cause of silicone breast implant rupture (50% to 64%

of cases).²² Other causes include underfilling and fold flaw from capsular contracture.

Leakage of silicone gel filler may be confined to the periprosthetic capsule (intracapsular rupture) or extend beyond and into the breast parenchyma (extracapsular rupture). One study reported that only 10% of intracapsular ruptures progressed extracapsularly, while 84% of patients with extracapsular involvement remained stable for up to 2 years,²³ indicating that intracapsular rupture may not portend worsening disease.¹¹

Implant rupture occurs silently in most cases, with no clinically detectable signs or symptoms. In other cases, patients may present with alterations in breast shape and size, sudden asymmetry, firmness, pronounced capsular contracture, contour irregularity, or pain.

Aside from physical examination, comprehensive diagnostic testing includes imaging—ultrasonography, mammography, computed tomography, and magnetic resonance imaging

Reoperation rates for primary breast augmentation surgery approach 20%

Irrigation with a triple antibiotic solution during the implant procedure decreases rates of infection and seroma

(MRI). Of these, MRI is the method of choice, with sensitivity and specificity exceeding 90% for detecting implant rupture.¹¹ Classic findings on MRI include the “linguine” sign from a deflating implant shell, or the teardrop sign from implant sagging. Classic findings on ultrasonography include the “snowstorm” sign of extracapsular rupture and the “stepladder” sign of intracapsular rupture.

Mammography effectively detects free silicone in breast tissue with extracapsular rupture (25% of ruptures according to some studies)²³; however, it cannot detect rupture within the implant capsule. As an aside, submuscular implant placement may interfere less with screening mammography than subglandular implants do.^{14,24}

Current FDA recommendations to detect implant rupture encourage women with silicone breast implants to undergo screening 3 years after implantation and then every 2 years thereafter; no long-term monitoring is suggested for saline implants.¹⁵ Many plastic surgeons evaluate silicone breast implant patients every 1 to 2 years for contracture and rupture.⁸ Of note, capsular contracture impairs the effectiveness of ultrasonography and may require MRI confirmation.¹¹

If implant rupture is confirmed, the current recommendation is to remove the implant and the capsule. Another implant may be placed depending on the patient’s preference. Rigorous washout remains a key feature of any surgical intervention for ruptured breast implants; however, in the event of extracapsular rupture, resection of silicone granulomas may also be required.¹¹

Reoperation rates for primary breast augmentation surgery approach 20% and are even higher for secondary augmentation over a patient’s lifetime—the highest rate of all aesthetic procedures.^{7,14}

■ CAPSULAR CONTRACTURE

Capsular contracture is the most common complication of breast augmentation,²⁵ typically presenting within the first postoperative year,^{26,27} and the risk increases over time.²⁸ It occurs with both silicone and saline breast implants.

In some studies, the incidence exceeded 4% in the first 2 years after surgery,²⁹ and near-

ly 50% by 10 years.³⁰ Other studies found rates of 0% to 20% over 13 years.²⁰

The etiology is not well understood and is presumed to be multifactorial, with proposed mechanisms and factors that include bacterial contamination, surface texturing, the implant pocket selected, the incision type, drain placement, antibiotic use, and smoking.²⁵

A meta-analysis from 17,000 implants found that the risk of capsular contracture was significantly higher when an implant was placed in a subglandular pocket than in a submuscular pocket,^{22,26} and that although texturing decreased capsular contracture compared with smooth implants, the effect was modest when a textured or smooth implant was placed in a submuscular location.²⁸ With regard to incision location, studies have reported that the incidence of capsular contracture is highest with transaxillary and periareolar incisions, and lowest with inframammary incisions.^{20,21}

The leading theory is that contamination of the implant (primarily from the mammary ducts) results in biofilm formation. Subclinical hematoma surrounding the implant may also provide key bacterial nutrients.²⁰

Textured implants induce a greater inflammatory response in the capsular tissue, resulting in a thicker capsule; however, contracture rates remain lower with textured than with smooth implants.^{14,31} Interestingly, lower rates of capsular contracture have been observed with later-generation, cohesive-gel, form-stable implants than with those of earlier generations.¹²

Although more research is needed, silicone implants appear to confer a higher risk of capsular contracture than saline implants.^{14,20}

Irrigating the breast pocket intraoperatively with triple antibiotic solution (bacitracin, cefazolin, and gentamicin) before placing the implant may decrease the capsular contracture rate.^{15,20}

Treatments for capsular contracture include pocket modifications such as capsulotomy (making releasing, relaxing incisions in the scar capsule encasing the implant), capsulectomy (removing portions of or the entire capsule), and replacing the implant in the other pocket (ie, if the original implant was subglandular, the replacement is placed in the submuscular pocket). Patients who have contractures that fail to respond to these treat-

ments may ultimately benefit from implant removal and autologous reconstruction (autoaugmentation) rather than implant replacement.^{32,33}

■ ADDITIONAL COMPLICATIONS

Other complications include infection, malposition, rippling, seroma, hematoma, and sensory alterations.

Irrigation during the implantation procedure with a triple antibiotic solution consisting of bacitracin, gentamycin, and cephalixin in normal saline decreases infection and seroma rates.^{15,20,34}

Some surgeons also choose to irrigate the pocket with a betadine solution, or to cleanse the skin with betadine and place sterile towels and redrape before inserting the implant. Additionally, many prefer using a sterile device much like a pastry funnel called a Keller funnel to insert the implant into the breast pocket.³⁵

Infection is less common with cosmetic augmentations than with implant-based breast reconstruction, likely because of healthier, well-vascularized tissue in patients undergoing cosmetic surgery than in those undergoing mastectomy.¹⁴

Seroma is thought to be a consequence of texturing, and more so with macro- vs micro-texturing. Though poorly understood, an association between texturing and double capsules has also been reported.^{12,20}

After primary breast augmentation, 10-year follow-up rates of capsular contracture, seroma, rippling, and malposition vary across the 3 major silicone implant manufacturers.¹² Hematoma and infection occur in less than 1% of primary augmentation patients.¹⁵

Malposition of the implant over time is less frequent with textured implants because of the higher coefficient of friction compared with smooth implants.^{6,8,15}

Visible skin rippling may be a consequence of texturing and also of thin body habitus, eg, in patients with a body mass index less than 18.5 kg/m². If the soft-tissue layer of the breast is thin, the natural rippling of smooth saline implant shells are more likely to show when placed in the subglandular pocket. Form-stable implants, by contrast, resist rippling.^{12,15}

Large implants and extensive lateral dissection can cause alterations in nipple sensation and sensory loss within lower breast pole skin. Axillary incisions may traumatize or damage the intercostobrachial nerve, resulting in upper inner arm sensory aberrations.

Ultimately, the 10-year incidence of secondary surgery ranges from 0% to 36% and the 10-year incidence of capsular contracture ranges from 11% to 19%.¹⁵ Additional cosmetic complaints after augmentation with implants include enlargement of the areola and engorgement of breast veins.¹⁴

■ BREAST CANCER AND DETECTION

Patients with or without implants do not seem to differ with regard to breast cancer stage upon detection, tumor burden, recurrence, or survival. However, more patients with implants may present with palpable masses, invasive tumors, axillary metastasis, and falsely negative mammograms.

Breast implants may actually facilitate cancer detection on physical examination by providing a more dense or stable surface upon which to palpate the breast tissue. Although they do not necessarily impair mastectomy or breast reconstruction, they may result in an increased rate of revision surgery after breast conservation therapy.^{24,36} Mammography remains the standard of care for radiologic diagnosis but can be further supported by MRI and ultrasonography if necessary in patients with implants.

■ AUTOIMMUNE DISEASES

Although concerns persist, multiple studies have demonstrated the safety of fourth- and fifth-generation silicone breast implants with regard to autoimmune disease.⁷

In various clinical studies in mastectomy patients who underwent breast reconstruction with either silicone implants or autologous tissue, no difference was found with regard to the incidence of autoimmune diseases.² Additionally, in meta-analyses of data from more than 87,000 women, no association was found between connective tissue disease and silicone breast implants.^{2,11} One study^{11,23} noted no increase in autoantibodies in patients with undamaged silicone implants vs patients who

Patients with or without implants do not seem to differ with regard to breast cancer stage upon detection, tumor burden, recurrence, or survival

experienced rupture.

Studies have also demonstrated that in children born to mothers with breast implants, the risk of rheumatic disease, esophageal disorders, congenital malformations, and death during the perinatal period is comparable with that in controls.³⁷ Another study, examining breastfeeding in women with silicone breast implants, showed no significant difference in silicon levels (used as a proxy for silicone) in breast milk compared with controls without implants; silicon levels were found to be significantly higher in cow's milk and store-bought formulas.³⁸

■ BREAST IMPLANT-ASSOCIATED ANAPLASTIC LARGE-CELL LYMPHOMA

Breast implant-associated anaplastic large-cell lymphoma (BIA-ALCL) is a subtype of T-cell lymphoma that develops in tissue adjacent to breast implants. It typically presents as breast swelling 2 to 38 years (mean of 8 years) after implant insertion.^{39,40} The swelling may be secondary to periprosthetic seroma formation or, more rarely, palpable disease in the axilla. Patients occasionally complain of pain and, rarely, constitutional symptoms.²⁰ BIA-ALCL is not a disease of the surrounding breast tissue, but rather of the fibrous periprosthetic capsule.²¹

Of note, there is no documented case involving smooth implants,^{41–43} but it may be related to fifth-generation textured implants.⁶ At present, it is not possible to definitively state which implant is associated with this condition; hence, more data are needed, and this association is currently under study.

The absolute risk of BIA-ALCL was reported in a Dutch study³⁹ as 1 in 35,000 by age 50, 1 in 12,000 by age 70, and 1 in 7,000 by age 75, with a number needed to harm of 6,920. Overall lifetime risk was estimated at 1 in 30,000 for women with textured implants in a 2015 US study.⁴⁰ In comparison, breast cancer risk is about 1 in 8 women. There is no apparent predilection for patients who underwent cosmetic augmentation vs reconstruction, or who received silicone vs saline implants.

The diagnosis is confirmed by ultrasonographically guided fine-needle aspiration

of seroma fluid and subsequent immunohistochemical testing for CD30-positive and ALK-negative T lymphocytes. Other than positron-emission tomography for staging after diagnosis confirmation, imaging is ineffective. Expert opinion does not recommend routine screening unless the aforementioned symptoms arise.

Treatment involves implant removal and total capsulectomy, with samples sent for pathology study with cytokeratin staining.¹² Of note, in all cases of BIA-ALCL in which the disease was limited to the circumscribed scar tissue of the breast capsule, complete surgical excision has proved curative, whereas incomplete capsulectomy portends a greater risk of recurrence and decreased survival.⁴⁴

In cases of advanced or recurrent ALCL, diagnosed late or inappropriately, the National Comprehensive Cancer Network recommends a multidisciplinary approach involving adjuvant chemotherapy and radiation.⁴⁴ Anecdotally, at our institution, we have recently treated several cases of advanced ALCL presenting with invasive chest wall masses with extirpative surgery and subsequent reconstruction with the assistance of our thoracic surgery colleagues, as well as the aforementioned multidisciplinary approach using adjuvant therapy.

The mechanism of this malignancy is currently under investigation, but the current theory implicates an exaggerated lymphoproliferative response to bacterial contamination of the capsule superimposed upon genetic factors in susceptible patients.^{42,43}

National societies advise plastic surgeons to discuss the risk of BIA-ALCL with all patients at the time of breast augmentation consultation and to report all confirmed cases to the PROFILE registry (Patient Registry and Outcomes for Breast Implants and Anaplastic Large Cell Lymphoma Etiology and Epidemiology).⁴⁵

■ ARE PATIENTS HAPPIER AFTERWARD?

Studies have shown that after undergoing breast augmentation surgery, patients note improvement in body image, and satisfaction rates range from 85% to 95% with respect to self-confidence and body image.⁴⁶ An evalu-

**Patients
report high
satisfaction
and
quality of life
afterward**

ation of patient responses on the validated BREAST-Q Augmentation Questionnaire showed the following satisfaction rates: breasts 83%, psychosocial well-being 88%, and sexual functioning 81%.¹⁵

Although epidemiologic studies have reported higher suicide rates in women with cosmetic breast implants, this likely stems from preoperative psychological factors and underscores the role of psychiatric referral in patients with a mental health history or in those whom the surgeon deems it necessary.⁴⁶

Several high-quality studies have demonstrated that quality of life and psychosocial functioning (including depression) markedly improve after breast augmentation surgery.⁴⁷

Among a cohort of Norwegian patients, breast implant surgery resulted in improved motivation to perform daily activities, as well as improved quality of life from both a psychosocial and aesthetic perspective.⁴⁸ Interestingly, a recent study reported that patients who underwent breast implant surgery alone reported greater satisfaction and psychosocial quality of life than patients who underwent combination breast augmentation and mastopexy (breast-lifting) surgery.⁴⁹

Additional data are needed to refine our understanding of the complex interplay between psychosocial factors before and after surgery in patients seeking and undergoing breast augmentation procedures. ■

REFERENCES

- Derby BM, Codner MA. Textured silicone breast implant use in primary augmentation: core data update and review. *Plast Reconstr Surg* 2015; 135(1):113–124. doi:10.1097/PRS.0000000000000832
- Maxwell GP, Gabriel A. Breast implant design. *Gland Surg* 2017; 6(2):148–153. doi:10.21037/gs.2016.11.09
- Gabriel A, Maxwell GP. The evolution of breast implants. *Clin Plast Surg* 2015; 42(4):399–404. doi:10.1016/j.cps.2015.06.015
- American Society of Plastic Surgeons. Procedural statistics trends 1992–2012. www.plasticsurgery.org/documents/News/Statistics/2012/plastic-surgery-statistics-full-report-2012.pdf. Accessed January 17, 2019.
- American Society of Plastic Surgeons. Plastic surgery statistics report 2016. www.plasticsurgery.org/documents/News/Statistics/2016/plastic-surgery-statistics-full-report-2016.pdf. Accessed January 17, 2019.
- Henderson PW, Nash D, Laskowski M, Grant RT. Objective comparison of commercially available breast implant devices. *Aesthetic Plast Surg* 2015; 39(5):724–732. doi:10.1007/s00266-015-0537-1
- Adams WP Jr, Mallucci P. Breast augmentation. *Plast Reconstr Surg* 2012; 130(4):597e–611e. doi:10.1097/PRS.0b013e318262f607
- Spears SL, Jespersen MR. Breast implants: saline or silicone? *Aesthet Surg J* 2010; 30(4):557–570. doi:10.1177/1090820X10380401
- Cronin TD, Gerow FJ. Augmentation mammoplasty: a new “natural feel” prosthesis. In: *Transactions of the Third International Conference of Plastic Surgery*: October 13–18, 1963, Washington, DC.
- Maxwell GP, Gabriel A. The evolution of breast implants. *Plast Reconstr Surg* 2014; 134(suppl 1):125–175. doi:10.1097/PRS.0000000000000348
- Hillard C, Fowler JD, Barta R, Cunningham B. Silicone breast implant rupture: a review. *Gland Surg* 2017; 6(2):163–168. doi:10.21037/gs.2016.09.12
- Derby BM, Codner MA. Textured silicone breast implant use in primary augmentation: core data update and review. *Plast Reconstr Surg* 2015; 135(1):113–124. doi:10.1097/PRS.0000000000000832
- Tugwell P, Wells G, Peterson J, et al. Do silicone breast implants cause rheumatologic disorders? A systematic review for a court-appointed national science panel. *Arthritis Rheum* 2001; 44(11):2477–2484. PMID:11710703
- Alpert BS, Lalonde DH. MOC-PS(SM) CME article: breast augmentation. *Plast Reconstr Surg* 2008; 121(suppl 4):1–7. doi:10.1097/01.prs.0000305933.31540.5d
- Hidalgo DA, Spector JA. Breast augmentation. *Plast Reconstr Surg* 2014; 133(4):567e–583e. doi:10.1097/PRS.0000000000000033
- ClinicalTrials.gov. Study of the safety and effectiveness of Motiva Implants®. <https://clinicaltrials.gov/ct2/show/NCT03579901>. Accessed January 17, 2019.
- Establishment Labs. Motiva Implants. <https://motivaimplants.com/why-motiva/innovation-for-enhanced-safety/>. Accessed January 17, 2019.
- Sforza M, Zaccacheddu R, Alleruzzo A, et al. Preliminary 3-year evaluation of experience with silksurface and velvetsurface Motiva silicone breast implants: a single-center experience with 5813 consecutive breast augmentation cases. *Aesthet Surg J* 2018; 38(suppl 2):S62–S73. doi:10.1093/asj/sjx150
- Huemer GM, Wenny R, Aitzetmüller MM, Duscher D. Motiva ergonomix round silksurface silicone breast implants: outcome analysis of 100 primary breast augmentations over 3 years and technical considerations. *Plast Reconstr Surg* 2018; 141(6):831e–842e. doi:10.1097/PRS.0000000000004367
- Lista F, Ahmad J. Evidence-based medicine: augmentation mammoplasty. *Plast Reconstr Surg* 2013; 132(6):1684–1696. doi:10.1097/PRS.0b013e3182a80880
- Namnoum JD, Largent J, Kaplan HM, Oefelein MG, Brown MH. Primary breast augmentation clinical trial outcomes stratified by surgical incision, anatomical placement and implant device type. *J Plast Reconstr Aesthet Surg* 2013; 66(9):1165–1172. doi:10.1016/j.bjps.2013.04.046
- Handel N, Garcia ME, Wixtrom R. Breast implant rupture: causes, incidence, clinical impact, and management. *Plast Reconstr Surg* 2013; 132(5):1128–1137. doi:10.1097/PRS.0b013e3182a4c243
- Hölmich LR, Friis S, Fryzek JP, et al. Incidence of silicone breast implant rupture. *Arch Surg* 2003; 138(7):801–806. doi:10.1001/archsurg.138.7.801
- McCarthy CM, Pusic AL, Disa JJ, Cordeiro PG, Cody HS 3rd, Mehrara B. Breast cancer in the previously augmented breast. *Plast Reconstr Surg* 2007; 119(1):49–58. doi:10.1097/01.prs.0000244748.38742.1f
- Egeberg A, Sørensen JA. The impact of breast implant location on the risk of capsular contraction. *Ann Plast Surg* 2016; 77(2):255–259. doi:10.1097/SAP.0000000000000227
- Wickman M. Rapid versus slow tissue expansion for breast reconstruction: a three-year follow-up. *Plast Reconstr Surg* 1995; 95(4):712–718. PMID:7892316
- Kjøller K, Hölmich LR, Jacobsen PH, et al. Epidemiological investigation of local complications after cosmetic breast implant surgery in Denmark. *Ann Plast Surg* 2002; 48(3):229–237. PMID:11862025
- Handel N, Jensen JA, Black Q, Waisman JR, Silverstein MJ. The fate of breast implants: a critical analysis of complications and outcomes. *Plast Reconstr Surg* 1995; 96(7):1521–1533. PMID:7480271
- Henriksen TF, Hölmich LR, Fryzek JP, et al. Incidence and severity of short-term complications after breast augmentation: results from a nationwide breast implant registry. *Ann Plast Surg* 2003; 51(6):531–539. doi:10.1097/01.sap.0000096446.44082.60
- Fernandes JR, Salinas HM, Broelsch GF, et al. Prevention of capsular contracture with photochemical tissue passivation. *Plast Reconstr Surg* 2014; 133(3):571–577. doi:10.1097/01.prs.0000438063.31043.79
- Wong CH, Samuel M, Tan BK, Song C. Capsular contracture in subglandular breast augmentation with textured versus smooth breast

- implants: a systematic review. *Plast Reconstr Surg* 2006; 118(5):1224–1236. doi:10.1097/01.prs.0000237013.50283.d2
32. **Gurunluoglu R, Sacak B, Arton J.** Outcomes analysis of patients undergoing autoaugmentation after breast implant removal. *Plast Reconstr Surg* 2013; 132(2):304–315. doi:10.1097/PRS.0b013e31829e7d9e
 33. **Gurunluoglu R, Shafighi M, Schwabegger A, Ninkovic M.** Secondary breast reconstruction with deepithelialized free flaps from the lower abdomen for intractable capsular contracture and maintenance of breast volume. *J Reconstr Microsurg* 2005; 21(1):35–41. doi:10.1055/s-2005-862779
 34. **Adams WP Jr, Rios JL, Smith SJ.** Enhancing patient outcomes in aesthetic reconstructive breast surgery using triple antibiotic breast irrigation: six-year prospective clinical study. *Plast Reconstr Surg* 2006; 118(7 suppl):465–525. doi:10.1097/01.prs.0000185671.51993.7e
 35. **Moyer HR, Ghazi B, Saunders N, Losken A.** Contamination in smooth gel breast implant placement: testing a funnel versus digital insertion technique in a cadaver model. *Aesthet Surg J* 2012; 32(2):194–199. doi:10.1177/1090820X11434505
 36. **Handel N.** The effect of silicone implants on the diagnosis, prognosis, and treatment of breast cancer. *Plast Reconstr Surg* 2007; 120(7 suppl 1):815–935. doi:10.1097/01.prs.0000286578.94102.2b
 37. **Kjøller K, Friis S, Lipworth L, McLaughlin JK, Olsen JH.** Adverse health outcomes in offspring of mothers with cosmetic breast implants: a review. *Plast Reconstr Surg* 2007; 120(7 suppl 1):1295–1345. doi:10.1097/01.prs.0000286571.93392.00
 38. **Sample JL.** Breast-feeding and silicone implants. *Plast Reconstr Surg* 2007; 120(7 suppl 1):1235–1285. doi:10.1097/01.prs.0000286579.27852.ed
 39. **de Boer M, van leeuwen FE, Hauptmann M, et al.** Breast implants and the risk of anaplastic large-cell lymphoma in the breast. *JAMA Oncol* 2018; 4(3):335–341. doi:10.1001/jamaoncol.2017.4510
 40. **McCarthy CM, Horwitz SM.** Association of breast implants with anaplastic large-cell lymphoma. *JAMA Oncol* 2018; 4(3):341–342. doi:10.1001/jamaoncol.2017.4467
 41. **American Society of Plastic Surgeons.** BIA-ALCL physician resources. www.plasticsurgery.org/for-medical-professionals/health-policy/bia-alcl-physician-resources. Accessed December 17, 2018.
 42. **The American Society for Aesthetic Plastic Surgery, Inc.** Member FAQs: latest information on ALCL. www.surgery.org/sites/default/files/Member-FAQs_1.pdf. Accessed January 17, 2019.
 43. **The American Society of Plastic Surgeons.** BIA-ALCL resources: summary and quick facts. www.plasticsurgery.org/for-medical-professionals/health-policy/bia-alcl-summary-and-quick-facts. Accessed January 17, 2019.
 44. **National Comprehensive Cancer Network.** T-cell lymphomas. www.nccn.org/professionals/physician_gls/pdf/t-cell.pdf.
 45. **The Plastic Surgery Foundation PROFILE Registry.** www.thepsf.org/research/registries/profile. Accessed January 17, 2019.
 46. **Sarwer DB.** The psychological aspects of cosmetic breast augmentation. *Plast Reconstr Surg* 2007; 120(7 suppl 1):1105–1175. doi:10.1097/01.prs.0000286591.05612.72
 47. **Rohrich RJ, Adams WP, Potter JK.** A review of psychological outcomes and suicide in aesthetic breast augmentation. *Plast Reconstr Surg* 2007; 119(1):401–408. doi:10.1097/01.prs.0000245342.06662.00
 48. **Kalaaji A, Bjertness CB, Nordahl C, Olafsen K.** Survey of breast implant patients: characteristics, depression rate, and quality of life. *Aesthet Surg J* 2013; 33(2):252–257. doi:10.1177/1090820X12473106
 49. **Kalaaji A, Dreyer S, Brinkmann J, Maric I, Nordahl C, Olafsen K.** Quality of life after breast enlargement with implants versus augmentation mastopexy: a comparative study. *Aesthet Surg J* 2018; 38(12):1304–1315. doi:10.1093/asj/sjy047

ADDRESS: Raffi Gurunluoglu, MD, PhD, Department of Plastic Surgery, A60, Dermatology and Plastic Surgery Institute, Cleveland Clinic, 9500 Euclid Avenue, Cleveland, OH 44195; gurunlr@ccf.org