

THE CLINICAL PICTURE

HIROKI MATSUURA, MD

Department of General Internal Medicine, Okayama City Hospital, Okayama, Japan; Department of General Internal Medicine, Mitoyo General Hospital, Kagawa, Japan

AKEMI SENOO, MD, PhD

Department of Dermatology, Mitoyo General Hospital, Kagawa, Japan; Department of Dermatology, Okayama Red-Cross Hospital, Okayama, Japan

MARI SAITO, MD

Department of Dermatology, Mitoyo General Hospital, Kagawa, Japan

YUKO FUJIMOTO, MD

Department of Dermatology, Mitoyo General Hospital, Kagawa, Japan; Department of Dermatology, Okayama University Hospital, Okayama, Japan

Norwegian scabies

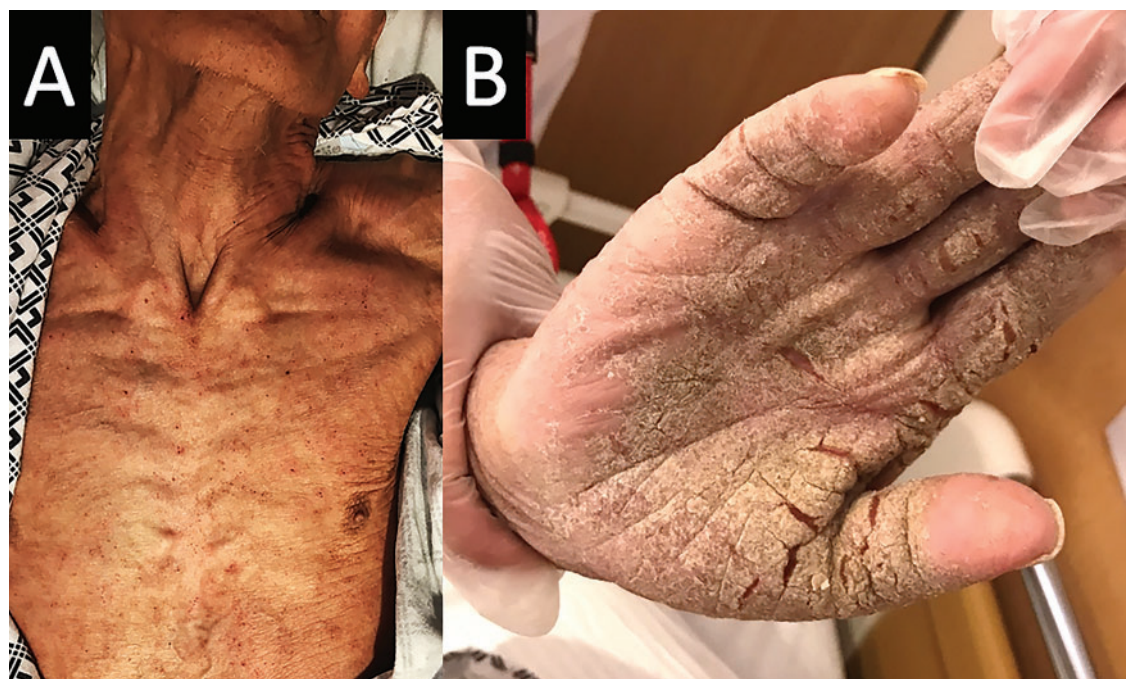

Figure 1. The hyperkeratotic lesions covered the trunk (A), arms, and hands (B).

Norwegian scabies is extremely contagious, and outbreaks can spread in institutions

A BEDRIDDEN 78-YEAR-OLD MAN with advanced dementia was transported to the dermatology outpatient department with a rash and intense itching over the entire body from the feet to the scalp. His medical history included diabetes mellitus, hypertension, and Alzheimer dementia. He had no history of allergies.

His vital signs were normal. Physical examination noted widespread crusted hyperkeratotic lesions on the trunk, arms, and hands (**Figure 1**). A potassium hydroxide mount of scrapings of the lesions revealed extensive infestation with *Sarcoptes scabiei*,¹ with a very high number of eggs and fecal pellets (**Figure**

2). This finding led to a diagnosis of crusted or Norwegian scabies, an extremely contagious form of scabies seen in immunocompromised, malnourished, and bedridden elderly or institutionalized patients.

■ DIAGNOSIS, TREATMENT, CONTROL

The differential diagnosis of Norwegian scabies includes psoriasis, eczema, contact dermatitis, insect bites, seborrheic dermatitis, lichen planus, systemic infection, palmoplantar keratoderma, and cutaneous lymphoma.²

Treatment involves eradicating the infestation with a topical ointment consisting of permethrin, crotamiton, lindane, benzyl benzoate, and sulfur, applied directly to the skin. However, topical treatments often can-

doi:10.3949/ccjm.86a.18081

**Oral ivermectin
200 µg/kg
on days 1, 2,
and 8 is a safe,
effective,
first-line
treatment**

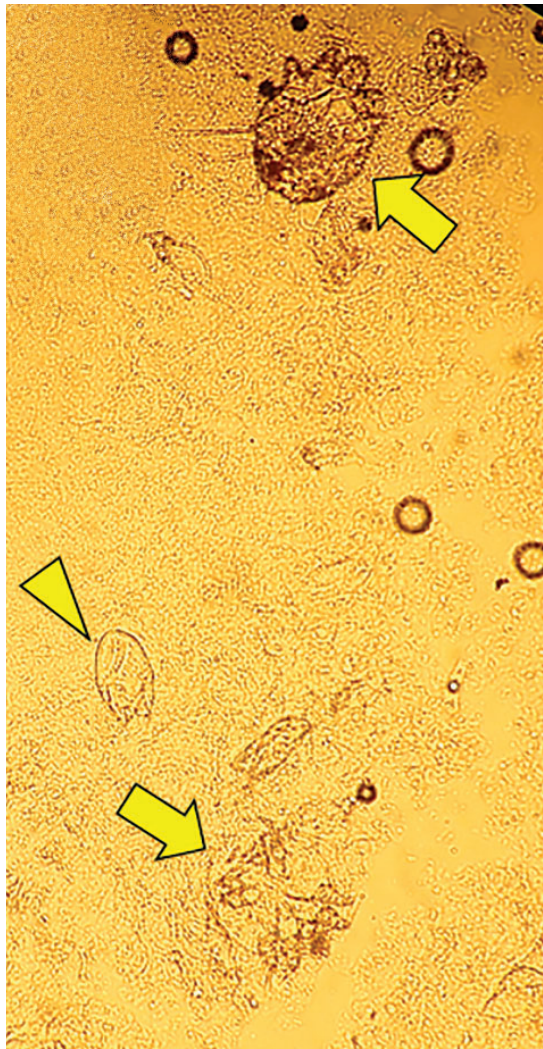


Figure 2. Microscopic study of hyperkeratotic lesion scrapings revealed scabies mites (arrows) and eggs (arrowhead).

not penetrate the crusted and thickened skin, leading to treatment failure. A dose of oral ivermectin 200 µg/kg on days 1, 2, and 8 is a safe, effective, first-line treatment for Nor-

wegian scabies, rapidly reducing scabies symptoms.³ Adverse effects of oral ivermectin are rare and usually minor.

Norwegian scabies is extremely contagious, spread by close physical contact and sharing of contaminated items such as clothing, bedding, towels, and furniture. Scabies mites can survive off the skin for 48 to 72 hours at room temperature.⁴ Potentially contaminated items should be decontaminated by washing in hot water and drying in a drying machine or by dry cleaning. Body contact with other contaminated items should be avoided for at least 72 hours.

Outbreaks can spread among patients, visitors, and medical staff in institutions such as nursing homes, day care centers, long-term-care facilities, and hospitals.⁵ Early identification facilitates appropriate management and treatment, thereby preventing infection and community-wide scabies outbreaks. ■

ACKNOWLEDGMENT: The authors would like to sincerely thank Paul Williams for his editing of the article.

REFERENCES

1. Leone PA. Scabies and pediculosis pubis: an update of treatment regimens and general review. *Clin Infect Dis* 2007; 44(suppl 3):S153–S159. doi:10.1086/511428
2. Siegfried EC, Hebert AA. Diagnosis of atopic dermatitis: mimics, overlaps, and complications. *J Clin Med* 2015; 4(5):884–917. doi:10.3390/jcm4050884
3. Salavastru CM, Chosidow O, Boffa MJ, Janier M, Tiplica GS. European guideline for the management of scabies. *J Eur Acad Dermatol Venereol* 2017; 31(8):1248–1253. doi:10.1111/jdv.14351
4. Khalil S, Abbas O, Kibbi AG, Kurban M. Scabies in the age of increasing drug resistance. *PLoS Negl Trop Dis* 2017; 11(11):e0005920. doi:10.1371/journal.pntd.0005920
5. Anderson KL, Strowd LC. Epidemiology, diagnosis, and treatment of scabies in a dermatology office. *J Am Board Fam Med* 2017; 30(1):78–84. doi:10.3122/jabfm.2017.01.160190

ADDRESS: Hiroki Matsuura, MD, Department of General Internal Medicine, Mitoyo General Hospital, 708 Himehama, Toyohama-cho, Kanonji-city, Kagawa, 769-1695 Japan; superonewex0506@yahoo.co.jp