

TABLE OF CONTENTS

FROM THE EDITOR

**Infection or not infection, that is the question—
Is procalcitonin the answer?** 297

What is different about procalcitonin that allows it to succeed as a biomarker where CRP and the ESR have failed?

B.F. MANDELL

THE CLINICAL PICTURE.....

Dabigatran-induced esophagitis 303

The tablets contain tartaric acid, and if they get stuck in the esophagus, the acid leaching out can damage the mucosa.

Y. KAJIHARA

1-MINUTE CONSULT

Can procalcitonin guide decisions about antibiotic management? 307

Yes, but clinical judgment must still be exercised.

R.J. FAKHERI

THE CLINICAL PICTURE.....

Pyoderma gangrenosum mistaken for diabetic ulcer 319

A man with type 2 diabetes, hypertension, anemia, and ulcerative colitis presented with an ulcer on his leg.

M.A. MUNOZ AND B.A. BABU

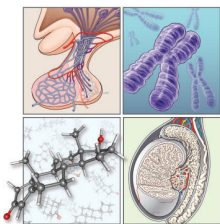
SYMPTOMS TO DIAGNOSIS



An obese 48-year-old man with progressive fatigue and decreased libido 321

Men with hypogonadism usually present with nonspecific symptoms.

A.N. FARKOUH AND A.A. ZAYED



CONTINUED ON PAGE 296

Online Features

Access

Cleveland Clinic Journal of Medicine content is readily available to all and is free of charge at www.ccjm.org.

Services


- Navigate quickly to articles in current and past issues via links on the home page and pull-down menus at the top of the page. Use the search function to find a specific article, or browse by topic or article type.
- Continuing medical education and maintenance of certification activities are accessible from article links and from a CME pull-down menu on the home page. Participation is free.
- Follow links on the home page to news, summaries of recent scientific meetings, and interactive quizzes.
- Click on the PDF symbol at the top of any online article to read, download, or print the article in PDF format.

Social Networking

To post a *CCJM* article to Facebook or Twitter, just click on the icon at the top of any online article.

www.ccjm.org

CONTINUED FROM PAGE 294

REVIEW  333

Evaluating and managing postural tachycardia syndrome

Therapy rarely cures it, but a multifaceted approach can substantially improve quality of life.

L.Y. LEI, D.S. CHEW, R.S. SHELDON, AND S.R. RAJ

REVIEW  345

Gastric outlet obstruction: A red flag, potentially manageable

Presume the cause to be a malignant tumor until proven otherwise.

A.H. KOOP, W.C. PALMER, AND F.F. STANCAMPIANO

DEPARTMENTS

Letters to the Editor 300

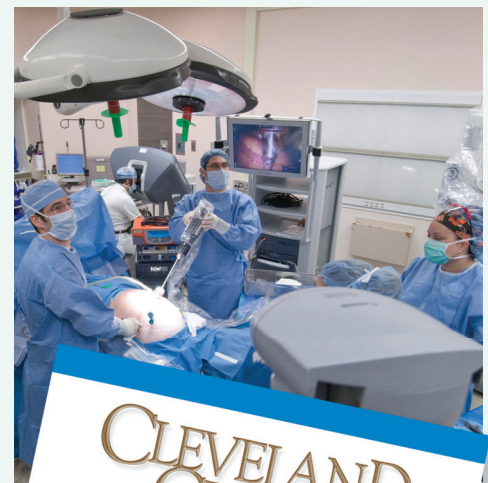Readers comment on aleukemic leukemia cutis (February 2019) and on human papillomavirus vaccination (March 2019).

CME Calendar 332

CME/MOC Instructions 354

Upcoming Features

- Type 2 diabetes: Evolving treatment
- Sleep apnea and stroke
- Colorectal cancer screening: FIT vs colonoscopy
- Giant cell arteritis: Update on an old disease
- Anti-Xa assays to guide heparin therapy
- Is imaging needed after thoracentesis?
- ACE inhibitors and ARBs: Benefits, adverse effects
- Should aspirin be stopped before noncardiac surgery?
- Functional heartburn: The brain-gut connection



CLEVELAND
CLINIC
JOURNAL OF
MEDICINE