

TABLE OF CONTENTS

FROM THE EDITOR

**The return of measles—
an unnecessary sequel** **365**

Why are we having such a tough time convincing people to get routine vaccines for themselves and for their kids?

B.F. MANDELL

THE CLINICAL PICTURE.....

**Disseminated invasive aspergillosis
in an immunocompetent patient** **369**

The patient, who has COPD, will require lifelong antifungal treatment.

J. McLAUGHLIN, E. LIBRE, A. MORGAN, AND S. DJURKOVIC

1-MINUTE CONSULT

**Is chest radiography routinely needed
after thoracentesis?** **371**

No, it should be done only in certain situations, for example, if pneumothorax is suspected.

A.E. MIRRAKHIMOV, A. BARBARYAN, T. AYACH, F.C. ESCARO, G. TALARI, AND A. GRAY

SYMPTOMS TO DIAGNOSIS

**A 69-year-old woman with double vision
and lower-extremity weakness** **374**

The onset was sudden, and the symptoms were gradually getting worse.

I. MIGDADY, M. MAYS, AND K.H. LEVIN

REVIEW

**Colorectal cancer screening:
Choosing the right test** **385**

The choice depends on patient preference, family history, and the likelihood of compliance.

G. MANKANEY, R.A. SUTTON, AND C.A. BURKE

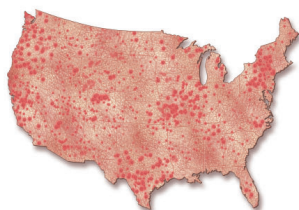
REVIEW



**Measles: A dangerous
vaccine-preventable disease returns** **393**

Vaccine refusal and global unrest have led to an alarming upswing in measles cases.

A. PORTER AND J. GOLDFARB



CONTINUED ON PAGE 364

Online Features

Access

Cleveland Clinic Journal of Medicine content is readily available to all and is free of charge at www.ccjm.org.

Services


- Navigate quickly to articles in current and past issues via links on the home page and pull-down menus at the top of the page. Use the search function to find a specific article, or browse by topic or article type.
- Continuing medical education and maintenance of certification activities are accessible from article links and from a CME pull-down menu on the home page. Participation is free.
- Follow links on the home page to news, summaries of recent scientific meetings, and interactive quizzes.
- Click on the PDF symbol at the top of any online article to read, download, or print the article in PDF format.

Social Networking

To post a *CCJM* article to Facebook or Twitter, just click on the icon at the top of any online article.

www.ccjm.org

CONTINUED FROM PAGE 362

REVIEW  400

**Women’s health 2019:
Osteoporosis, breast cancer, contraception,
and hormone therapy**

Vignettes with practical advice based on current literature.

A.C. MORENO, S.K. SAHNI, T.L. SMITH, AND P. BATUR

REVIEW  407

**A sleeping beast:
Obstructive sleep apnea and stroke**

Up to two-thirds of patients who have had a stroke have obstructive sleep apnea afterward, with worse outcomes.

Z. McKEE AND D.H. AUCKLEY

REVIEW  417

**Anti-Xa assays:
What is their role today
in antithrombotic therapy?**

Should clinicians abandon the aPTT for monitoring heparin therapy in favor of anti-Xa assays?

E. HUTT CENTENO, M. MILITELLO, AND M.P. GOMES

DEPARTMENTS 368

Letters to the Editor 368

A reader comments about use of the red blood cell distribution width in the complete blood cell count (March 2019).

Correction 392

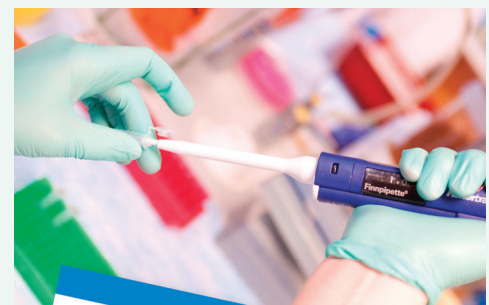The article: Azim S, Nasr C. Subclinical hypothyroidism: When to treat. *Cleve Clin J Med* 2019; 86(2):101–110. doi:10.3949/ccjm.86a.17053 contained an error.

CME Calendar 416

CME/MOC Instructions 426

Upcoming Features

- Type 2 diabetes: Evolving treatment
- Giant cell arteritis: Update on an old disease
- You can observe a lot by watching
- Should aspirin be stopped before noncardiac surgery?
- Use ACEs and ARBs, but watch K⁺ and GFR
- Ambulatory ECG in the smart phone era
- When does acute pyelonephritis require imaging?
- Functional heartburn: The brain-gut connection
- Hemorrhoids: Surgery vs conservative management



CLEVELAND
CLINIC
JOURNAL OF
MEDICINE