

TABLE OF CONTENTS

FROM THE EDITOR

Deciding when a picture is worth a thousand words and several thousand dollars 509

Physical examination is cheap but not highly reproducible. Imaging is expensive but may be more sensitive and specific.

B.F. MANDELL

THE CLINICAL PICTURE.....

Osteonecrosis of the femoral head with subchondral collapse 511

A 45-year-old woman had been taking corticosteroids long-term after organ transplant.

N.S. PIUZZI, H.K. ANIS, AND G.F. MUSCHLER

SMART TESTING

When does acute pyelonephritis require imaging? 515

Imaging is recommended for those at risk of complications.

M.E. LACY, N. SIDHU, AND J. MILLER

1-MINUTE CONSULT

Should we stop aspirin before noncardiac surgery? 518

It depends on the type of surgery and the reason the patient is taking aspirin.

A. PRABHAKARAN AND C. WHINNEY

EDITORIAL

Aspirin: 4,000 years and still learning 522

What we know about aspirin—and what we still need to learn.

K.C. CUMMINGS

COMMENTARY

Primary care: Practice meets technology 525

Technology has infiltrated all parts of our lives. Physicians need to adapt and adjust.

C.I. PRAVIA AND Y.M. DIAZ

CONTINUED ON PAGE 508

Online Features

Access

Cleveland Clinic Journal of Medicine content is readily available to all and is free of charge at www.ccm.org.

Services

- Navigate quickly to articles in current and past issues via links on the home page and pull-down menus at the top of the page. Use the search function to find a specific article, or browse by topic or article type.
- Continuing medical education and maintenance of certification activities are accessible from article links and from a CME pull-down menu on the home page. Participation is free.
- Follow links on the home page to news, summaries of recent scientific meetings, and interactive quizzes.
- Click on the PDF symbol at the top of any online article to read, download, or print the article in PDF format.

Social Networking

To post a *CCJM* article to Facebook or Twitter, just click on the icon at the top of any online article.

www.ccm.org

CONTINUED FROM PAGE 506

EDITORIAL

Running in place: The uncertain future of primary care internal medicine **530**

If we don't demand change, who will be there to take care of us when we grow old?

C. NIELSEN AND P. BATUR

SYMPTOMS TO DIAGNOSIS **CME MOC ACCREDITED**

An unusual cause of bruising **535**

The coagulation assay, particularly the prothrombin time and aPTT, is key in initially assessing a bleeding abnormality.

T. ATIEH AND A. LICHTIN

REVIEW **CME MOC ACCREDITED**

Adults with autism spectrum disorder: Updated considerations for healthcare providers **543**

Social support, community programs, and behavioral therapies can help. Caregivers may also need support.

C. SWETLIK, S.E. EARP, AND K.N. FRANCO

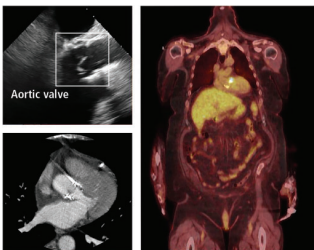
EDITORIAL

Where have all the children gone? Intentional communities for adults with autism **554**

Children with ASD grow to be adults with ASD, with complex healthcare needs.

C.R. BRASS AND D.J. MANDELL

REVIEW **CME MOC ACCREDITED**



Infective endocarditis: Beyond the usual tests **559**

Newer imaging tests are increasingly used as alternatives or adjuncts to echocardiography for selected patients.

N. MGBOJIKWE, S.R. JONES, T.M. LEUCKER, AND D.J. BROTMAN

DEPARTMENTS

Letters to the Editor **514**

A reader raises questions about diabetic gastroparesis (April 2019).

CME Calendar **553**

CME/MOC Instructions **Inside back cover**

Upcoming Features

- **Diabetes drugs: Benefits beyond A_{1c}**
- **Gabapentin for alcohol use disorder: Opportunity for abuse?**
- **Systemic sclerosis and the heart: What to look for**
- **Migraine lifestyle hacks**
- **Functional heartburn: The brain-gut connection**
- **Cardio-obstetrics: Better maternal outcomes**
- **On ACEs and ARBs: Managing K⁺, renal function**
- **Update on STI diagnosis**
- **Does my patient need IV maintenance fluid?**
- **Shocking news: Defibrillator safety**



CLEVELAND CLINIC JOURNAL OF MEDICINE