

TABLE OF CONTENTS

FROM THE EDITOR

A sneaky vascular disease **581**
 Cholesterol embolization syndrome may provide insights into atherosclerotic disease.
 Brian F. Mandell, MD, PhD

THE CLINICAL PICTURE

Verrucous plaques on the face, dysphagia, and limb weakness **587**
 An itchy bump on the upper lip rapidly grew and spread.
 Kerry Hennessy, MD; Mahmoud Shorman, MD, MHA

THE CLINICAL PICTURE

Miliary tuberculosis in a patient with end-stage liver disease **590**
 Chest radiography showed patchy left basilar consolidation with subtle, diffuse interstitial opacities.
 Victoria Poplin, MD; Brent Harbaugh, DO, MA; Matthias Salathe, MD; Nathan C. Bahr, MD, MA

1-MINUTE CONSULT

When is contrast needed for abdominal and pelvic CT? **595**
 The decision to use contrast depends on the diagnosis suspected.
 Mark Radetic, MD; Robert DeVita, MD; John Haaga, MD

1-MINUTE CONSULT

Should we give triple therapy to patients with atrial fibrillation after percutaneous intervention? **599**
 Triple therapy is aggressive and carries high risks of bleeding and death.
 Asim Kichloo, MD; Michael M. Aljadah, MD; Farah Wani, MD; Sindhura Ananthaneni, MD

COMMENTARY

Overcoming obesity: Weight-loss drugs are underused **602**
 Successful management of obesity requires a multifaceted approach.
 Amjad Kanj, MD, MPH, Diane Levine, MD, FACP

SYMPTOMS TO DIAGNOSIS

Peripheral artery disease and unusual skin findings **605**
 A 68-year-old man was admitted because of worsening skin problems in his legs.
 Aaron Andrew Heigaard Smith, MD; Erin Luxenberg, MD; Roberta Meyers, MD, MPH

CONTINUED ON PAGE 580

CONTINUED FROM PAGE 578

REVIEW

Promoting resiliency in adolescents during a pandemic: A guide for clinicians and parents **613**

Parents of adolescents may face unique challenges in helping their children navigate changes to their daily routine.

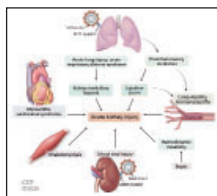
Ellen S. Rome, MD, MPH; Perry B. Dinardo, MA; Veronica E. Issac, MD

REVIEW

COVID-19 and the kidney **619**

The kidney may be a target of SARS-CoV-2 infection.

Mohamed Hassanein, MD; Yeshwanter Radhakrishnan, MD; John Sedor, MD; Tushar Vachharajani, MD; Vidula T. Vachharajani, MD; Joshua Augustine, MD; Sevag Demirjian, MD; George Thomas, MD



REVIEW **CME** **MOC**

Hospital-acquired and ventilator-associated pneumonia: Diagnosis, management, and prevention **633**

Better diagnosis, management, and prevention are needed.

Anita Rae Modi, MD; Christopher S. Kovacs, MD

LETTERS TO THE EDITOR

The R in PRES **584**

Posterior reversible encephalopathy syndrome lacks universal diagnostic criteria.

Amado Jiménez-Ruiz, MD; Miguel García-Grimshaw, MD; Juan Andrés Calderón Martínez, MD; Isael Reyes-Melo, MD

LETTERS TO THE EDITOR

Trousseau sign and syndrome: Erroneous terms **585**

Trousseau never described a constellation of symptoms in this disease.

Steven Yale, MD, MACP; Halil Tekiner, PhD; Joseph Mazza, MD; Eileen Scott Yale, MD

LETTERS TO THE EDITOR

Trousseau sign and syndrome: Erroneous terms. In reply **586**

Trousseau sign should continue to be taught and recognized on physical examination.

Satish S. Maharaj, MD; Michael Omar, MBBS; Karan Seegobin, MBBS; Simone Chang, MBBS

DEPARTMENTS

CME Calendar **583**

CME/MOC Instructions **640**