

TABLE OF CONTENTS

FROM THE EDITOR	
2020: A year like no other	710
Veracity and bias are issues we address on a daily basis.	
Brian F. Mandell, MD, PhD	
THE CLINICAL PICTURE	
Hypothyroidism, eyelash loss	717
Testing showed high TSH, low T ₄ , and antithyroid antibodies.	
Hiroki Matsuura, MD; Yu Suganami, MD, PhD	
THE CLINICAL PICTURE	
Air embolism after peripheral IV contrast injection	718
As little as 2 to 3 mL of air in the cerebral circulation can be fatal.	
Justin Goodwin, MS; Karthik Gnanapandithan, MD, MS, FHM	
SMART TESTING	
Does this young adult patient need a hip radiograph?	721
Hip fractures are uncommon in adults under age 50.	
Christina Stull, MD, MBA; Alejandro Moreno, MBBS, MPH, JD, MACP	
COMMENTARY	
Is regular oxygen supplementation safe for obese postoperative patients?	723
Caution for some, but no evidence to support withholding it altogether.	
Roop Kaw, MD; Anthony G. Doufas, MD, PhD	
COVID-19 CURBSIDE CONSULTS	
Neurologic complications of COVID-19	729
Human coronaviruses, including SARS-CoV-2, can be neurotropic.	
Catherine E. Hassett, DO; Aron Gedansky, MD; Ibrahim Migdady, MD; Adarsh Bhimraj, MD; Ken Uchino, MD; Sung-Min Cho, DO	
SYMPTOMS TO DIAGNOSIS	
Fever in a lung transplant recipient	735
A 36-year-old woman presents with high fevers, chills, nausea, decreased oral intake, and diarrhea.	
Graham Walter, MD; Hanna Lyubetska, MD, MSc; Aditya Sharma, MD, FRCPC	
SYMPTOMS TO DIAGNOSIS	
Acute pancreatitis secondary to hypertriglyceridemia	742
A man presents with acute severe abdominal pain and triglycerides 5,250 mg/dL.	
Michael A. Munoz, MD; Kaviya Sathyakumar, MD; Benson A. Babu, MD, MBA	

CONTINUED ON PAGE 708

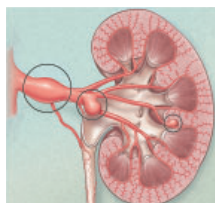
CONTINUED FROM PAGE 706

REVIEW

Autonomous sensory meridian response: Your patients already know, do you? 751

People are actively seeking it out as a type of complementary therapy.

Neha V. Reddy; Arya B. Mohabbat, MD, FACP



REVIEW **CME MOC**

Optimal surveillance and treatment of renal and splenic artery aneurysms 755

Indications for repair are based on aneurysm location and risk factors for rupture.

Tom Kai Ming Wang, MBCHB, MD(res), FRACP; Milind Y. Desai, MD

REVIEW

Long-term consequences of prematurity 759

Survivors of premature birth may have adverse health effects later in life.

Cristina I. Pravia, MD; Merline Benny, MD

LETTERS TO THE EDITOR

COVID-19 coagulopathy 712

Skepticism of high-intensity prophylaxis for patients with D-dimer ≥ 3.0 $\mu\text{g/mL}$.

Anup Katyal, MD

LETTERS TO THE EDITOR

COVID-19 coagulopathy. In Reply 712

An attempt to balance the potential risks and benefits of intensified prophylaxis.

Simon R. Mucha, MD; Siddharth Dugar, MD; Keith McCrae, MD; Douglas Joseph, DO; John Bartholomew, MD; Gretchen L. Sacha, PharmD, RPh, BCCP; Michael Militello, PharmD, RPh, BCPS

LETTERS TO THE EDITOR

Assessing stable coronary artery disease 713

Differences between the coronary calcium score and CT coronary angiography.

Taher Modarressi, MD

LETTERS TO THE EDITOR

Assessing stable coronary artery disease. In reply 714

CT angiography is the appropriate test to exclude left main disease.

Vinayak Nagaraja, MD; A. Michael Lincoff, MD

LETTERS TO THE EDITOR

Dexamethasone or hydrocortisone in COVID-19? 715

Dexamethasone should be favored over hydrocortisone.

Chia Siang Kow; Syed Shahzad Hasan

DEPARTMENTS

CME Calendar 709

CME/MOC Instructions 768