

## Online Features

### Access

Cleveland Clinic Journal of Medicine content is readily available to all and is free of charge at [www.ccjm.org](http://www.ccjm.org). On your first visit, we will ask you to take a few minutes to register, but subsequent visits will be unencumbered except for an occasional request for your e-mail address when you visit using another device (eg, mobile phone, tablet).

### Services

- Navigate quickly to articles in current and past issues via links on the home page and pull-down menus at the top of the page. Use the search function to find a specific article, or browse by topic or article type.
- Continuing medical education activities are accessible from article links and from a CME pull-down menu on the home page. Participation is free.
- Follow links on the home page to news, summaries of recent scientific meetings, and interactive quizzes.
- Click on the PDF symbol at the top of any online article to read, download, or print the article in PDF format.

### Social Networking

To post a *CCJM* article to Facebook or Twitter, just click on the icon at the top of any online article.

[www.ccjm.org](http://www.ccjm.org)

APRIL 2020

## TABLE OF CONTENTS

<b>FROM THE EDITOR</b> .....	
<b>The under- and overrecognized, and the elephant in the room</b>	<b>189</b>
We internists must recognize the pine cones without losing our vision of the forest.	
Brian F. Mandell, MD, PhD	
<b>THE CLINICAL PICTURE</b> .....	
<b>Paroxysmal finger hematoma</b>	<b>194</b>
This benign, self-limiting condition predominantly affects middle-aged women.	
Daan J.L. van Twist, MD, PhD; Wim Hermans; Guy J.M. Mostard, MD	
<b>THE CLINICAL PICTURE</b> .....	
<b>Constitutional symptoms, pathologic PET-CT</b>	<b>195</b>
PET-CT showed diffuse hypermetabolism of the great vessel walls, compatible with large-vessel giant cell arteritis.	
Julia L. Riera, MD; Jorge L. Musuruana, MD; Fernando Faccio, MD; Javier A. Cavallasca, MD	
<b>THE CLINICAL PICTURE</b> .....	
<b>Trousseau syndrome</b>	<b>199</b>
Examination revealed multiple bluish macules and 2 palpable thrombosed superficial veins in the right popliteal fossa.	
Satish Maharaj, MBBS; Michael Omar, MBBS; Karan Seegobin, MBBS; Simone Chang, MBBS	
<b>1-MINUTE CONSULT</b> .....	
<b>Can I use direct oral anticoagulants to treat cancer-associated venous thromboembolism?</b>	<b>201</b>
DOACs are increasingly replacing low-molecular-weight heparins for this purpose.	
Oluwadunni Emiloju, MD; Sorab Gupta, MD; Claudia Dourado, MD	
<b>REVIEW</b> .....	<b>CME   MOC</b>
<b>To scan or not to scan? DXA in postmenopausal women</b>	<b>205</b>
DXA is strongly recommended for women age 65 and older, but not so much for younger postmenopausal women.	
Kristi Tough DeSapri, MD, CCD, NCMP; Rachel Brook, MD	

CONTINUED ON PAGE 188

CONTINUED FROM PAGE 187

CURRENT DRUG THERAPY .....

**CGRP antagonists for decreasing migraine frequency: New options, long overdue** 211

CGRP drugs are an exciting frontier, but migraine management is still a combination of lifestyle changes plus treatment.

Julia Bucklan, DO; Zubair Ahmed, MD

EDITORIAL .....

**Preventing migraine: The old and the new** 219

Roughly half of patients taking any preventive medication have a 50% reduction in migraine frequency.

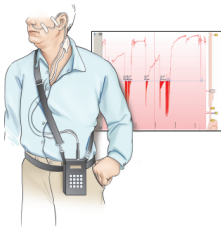
Glen D. Solomon, MD

REVIEW ..... CME MOC

**GERD: A practical approach** 223

PPIs are the first-line medical therapy. Endoscopic and surgical options are pursued only if medical therapy fails.

Andrew Young, DO; Mythri Anil Kumar, MD; Prashanthi N. Thota, MD, FACC



REVIEW ..... CME MOC

**ACC/AHA lipid guidelines: Personalized care to prevent cardiovascular disease** 231

Risk assessment, drugs, patient subgroups, value of therapy, personalized plans, and shared decision-making.

Cara Reiter-Brennan; Albert D. Osei, MD, MPH; S.M. Iftekhar Uddin, MBBS, MSPH; Olusola A. Orimoloye, MD, MPH; Olufunmilayo H. Obisesan, MD, MPH; Mohammadhassan Mirbolouk, MD; Michael J. Blaha, MD, MPH; Omar Dzaye, MD, PhD

LETTERS TO THE EDITOR .....

**Infective endocarditis: Don't forget the ICE** 191

A recent article did not mention intracardiac echocardiography.

Faris G. Araj, MD; Michael Luna, MD

**In reply: Infective endocarditis: Don't forget the ICE** 192

Echocardiography relies on finding an anatomic abnormality, whereas <sup>18</sup>F-FDG-PET is a functional examination.

Nkemdilim Mgbajikwe, MD; Steven R. Jones, MD; Thorsten M. Leucker, MD, PhD; Daniel J. Brotman, MD

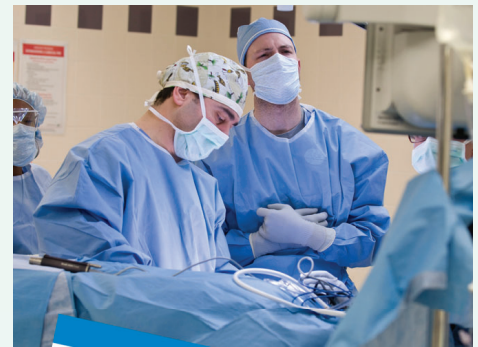DEPARTMENTS .....

**CME Calendar** 190

**CME/MOC Instructions** Inside back cover

# Upcoming Features

- Bronchoscopic lung reduction for emphysema
- Steroid-associated bone loss
- Perinatal depression
- Cancer-associated thrombosis: Predict, prevent, treat
- 'I want a doctor who looks like me'
- Short QT and sudden cardiac death
- Troponin testing in acute coronary syndrome
- Cutaneous side effects of biologic medications
- Pneumonia in alcohol use disorder



CLEVELAND CLINIC JOURNAL OF MEDICINE