

TABLE OF CONTENTS

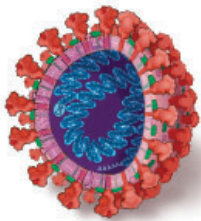
FROM THE EDITOR

Perioperative infection: Are we sure what to focus on? 317

Which immunosuppressive drugs pose the greater danger in the perioperative period: the newer biologics or corticosteroids?

Brian F. Mandell, MD, PhD

COVID-19 CURBSIDE CONSULTS



COVID-19: Coronavirus replication, pathogenesis, and therapeutic strategies 321

Understanding the virus and how it causes disease points the way to potential treatments.

Cornelia C. Bergmann, PhD; Robert H. Silverman, PhD

COVID-19 CURBSIDE CONSULTS

COVID-19 serologic testing: FAQs and caveats 329

Is serology a possible alternative to direct testing?

Kamran Kadkhoda, PhD, D(ABMM), D(ABMLI)

THE CLINICAL PICTURE

Rigid airway 334

A 23-year-old woman presents with nonproductive cough and shortness of breath.

Masaki Itagane, MD; Hiroyuki Yano, MD; Tomoo Kishaba, MD; Mitsuyo Kinjo, MD, MPH

THE CLINICAL PICTURE

Vertebral fractures after denosumab cessation 337

The patient had a 6-month history of lumbar and dorsal back pain, initially suspected to be facet arthrosis.

Jolan Dupont, MD; Michaël R. Laurent, MD, PhD; Lenore Dedeyne, MSc; Frank P. Luyten, MD, PhD; Evelien Gielen, MD, PhD; Marian Dejaeger, MD, PhD

EDITORIAL

Denosumab cessation 339

Bone loss is rapid if patients miss injections. Clinicians can take extra measures to ensure patients get appropriate treatment.

Chad L. Deal, MD

CONTINUED ON PAGE 316

Online Features

Access

Cleveland Clinic Journal of Medicine content is readily available to all and is free of charge at www.ccm.org.

Services

- Navigate quickly to articles in current and past issues via links and pull-down menus at the top of the home page. Use the search function to find a specific article, or use the pull-down content menu to browse articles.
- Continuing medical education and maintenance of certification activities are accessible from the CME/MOC pull-down menu on the home page. Participation is free.
- Follow links on the home page to a calendar of upcoming CME events.
- Click on the PDF symbol at the top of any online article to read, download, or print the article in PDF format.

Social Networking

To post a *CCJM* article to Facebook or Twitter, just click on the icon at the top of any online article.

www.ccm.org

CONTINUED FROM PAGE 314

1-MINUTE CONSULT

Is it safe to continue biologic agents during surgery in patients with inflammatory bowel disease? 343

Patients taking monoclonal antibodies can continue taking them, but small-molecule drugs should be withheld.

Zain Moosvi, MD; Alexander Abadir, MD; Jacqueline Duong, BS; Douglas Nguyen, MD

MEDICAL GRAND ROUNDS CME MOC

Recurrent Clostridioides difficile infection: Recognition, management, prevention 347

Episodes follow disruption of colonic microbiota, usually within 4 weeks of completing antibiotic therapy.

Constantine Tsigrelis, MD

REVIEW CME MOC

Medical complications of anorexia nervosa 361

Many of these complications resolve with treatment and weight gain, but others can lead to permanent damage.

Jeana Cost, LPC, CEDS; Mori J. Krantz, MD; Philip S. Mehler, MD, FACP, FAED

REVIEW CME MOC

Liposuction: Concepts, safety, and techniques in body-contouring surgery 367

In addition to its purely aesthetic uses, liposuction is an important adjunct in reconstructive surgery.

Shannon Wu, BA; Demetrius M. Coombs, MD; Raffi Gurunian, MD, PhD

LETTERS TO THE EDITOR

Familial hypercholesterolemia: Clarifications 320

Comments on xanthoma vs xanthelasmas, and goal LDL-C.

Taher Modarressi, MD

In reply: Familial hypercholesterolemia: Clarifications 320

The authors' response.

Nishant P. Shah, MD, FACC; Haitham M. Ahmed, MD; W. H. Wilson Tang, MD

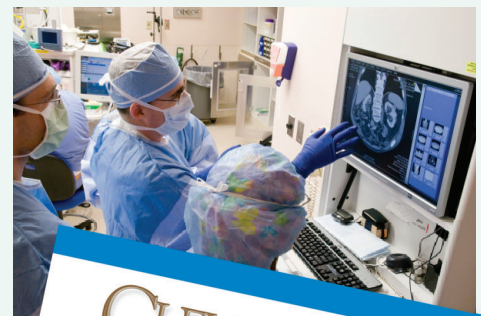DEPARTMENTS

CME Calendar 319

CME/MOC Instructions 376

Upcoming Features

- COVID-19 Curbside Consults: Clinical presentation, Cytokine storm, Chest imaging, Coagulopathy, Myocardial injury. More at www.ccm.org
Troponin: Out with the old, in with the new
Glucocorticoid-induced bone loss
Short QT and sudden cardiac death
Optimizing documentation for Medicare reimbursement
Fixing secondary hypertension
Pneumonia and alcohol use disorder
Updated asthma guidelines
Hospital-acquired pneumonia



CLEVELAND CLINIC JOURNAL OF MEDICINE