

TABLE OF CONTENTS

FROM THE EDITOR

A seaworthy nautical tale and a pictured rash 453

In history's first randomized controlled trial, James Lind gave 2 sailors lemons and oranges, and they got better.

Brian F. Mandell, MD, PhD

COVID-19 CURBSIDE CONSULTS **CME | MOC**

Coagulopathy in COVID-19: Manifestations and management 461

Prophylaxis against venous thromboembolism is recommended for all patients hospitalized with COVID-19.

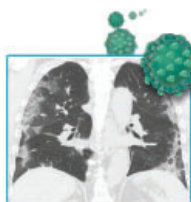
Simon R. Mucha, MD; Siddharth Dugar, MD; Keith McCrae, MD; Douglas Joseph, DO, John Bartholomew, MD; Gretchen L. Sacha, PharmD, RPh, BCCCP; Michael Militello, Pharm D, RPh, BCPS

COVID-19 CURBSIDE CONSULTS

Thoracic imaging in COVID-19 469

Typical findings include bilateral multifocal parenchymal opacities, predominantly in the peripheral and lower zones.

Ruchi Yadav, MD; Debasis Sahoo, MD, FCCP; Ruffin Graham, MD



THE CLINICAL PICTURE

Acute dacryocystitis 477

Inflammation of the lacrimal sac is related to obstruction, which can be primary or secondary.

Satvinder Singh Bakshi, MS, DNB

THE CLINICAL PICTURE

Scurvy: Old, but still relevant 478

A patient with alcohol use disorder presented with progressively worsening fatigue, dyspnea on exertion, and easy bruising.

Mohamed A. Elfeki, MD, MSc; Tyler Schwiesow, MD, FACP; Zeeshan Jawa, MD, FACP

1-MINUTE CONSULT

Should we monitor troponin up to peak value when evaluating for acute coronary syndrome? 480

No. Once troponin is over the 99th percentile, finding the peak value does not aid in diagnosis.

Nolan Anderson, MD; Samuel T. Ives, MD; Michelle D. Carlson, MD; Fred Apple, PhD, DABCC

EDITORIAL

Cardiac troponin testing: Goodbye, 'troponinemia' 483

Any troponin elevation is prognostically important; dismissing it as "troponinemia" is no longer a viable strategy.

Anirudh Kumar, MD; Divyang R. Patel, MD; Venugopal Menon, MD

CONTINUED ON PAGE 452

CONTINUED FROM PAGE 450

REVIEW **CME MOC**
Rhinosinusitis and the role of imaging **485**

Imaging should only be used in complicated sinus infections, in recurrent or chronic sinus disease, or in surgical planning.

Nicole Frerichs, DO; Andrei Brateanu, MD, FACP

REVIEW **CME MOC**
Pneumonia and alcohol use disorder: Implications for treatment **493**

Patients with alcohol use disorder are at increased risk for *Streptococcus pneumoniae* but not resistant gram-negative infections.

Niyati M. Gupta, MD; Abhishek Deshpande, MD, PhD; Michael B. Rothberg, MD, MPH

REVIEW **CME MOC**
Irritable bowel syndrome with diarrhea: Treatment is a work in progress **501**

Understanding of its mechanisms is progressing, and treatments are increasingly targeted to the individual etiology.

Michael Kurin, MD; Gregory Cooper, MD

LETTERS TO THE EDITOR

Perinatal depression **456**

Elise Laflamme, MD

In Reply: Peripartum depression **456**

Maureen Sayres Van Niel, MD; Jennifer L. Payne, MD

DXA after menopause **457**

Michael Balkin, MD

In reply: DXA after menopause **457**

Kristi Tough DeSapri, MD; Rachel Brook, MD

Aspirin for primary prevention **458**

Elise Henning, MD, MEd

In reply: Aspirin for primary prevention **458**

Aldo L. Schenone, MD; A. Michael Lincoff, MD

DEPARTMENTS

CME Calendar **455**

Correction: Liposuction **476**

CME/MOC Instructions **512**