

TABLE OF CONTENTS

FROM THE EDITOR

We have a greater understanding of ‘cardiac syndrome X,’ but questions remain **532**

A better understanding of angina due to ischemia and no obstructive coronary artery disease has led to recognition of coronary microvascular dysfunction in many of these patients.

Brian F. Mandell, MD, PhD

THE CLINICAL PICTURE

Revisiting the ‘great masquerader’ **536**

An HIV patient presents with scaly brown lesions on the palms and soles, mildly painful oral erosions, and a buzzing sound in the right ear for the past 20 days.

Raihan Ashraf, MD; Rahul Mahajan, MD; Debajyoti Chatterjee, DM; Kollabathula Arpitha, MD

THE CLINICAL PICTURE

Chest pain: The importance of serial ECGs **538**

Repeat electrocardiograms in a 44-year-old man who presented with severe hypertension revealed de Winter and Wellens patterns.

Rene Jansen van Rensburg, MBChB, MD; Jason Schutte, MBChB; Thomas de Beenhouwer, MD

EDITORIAL

Fungus among us: A poster child for diagnostic stewardship **541**

When interpreting the significance of *Aspergillus* species in respiratory culture, first ask if the culture was clinically indicated, or if this was an incidental finding.

Sherif Beniameen Mossad, MD, FACP, FIDSA, FAST

1-MINUTE CONSULT

Is *Aspergillus* isolated from respiratory cultures clinically significant? **543**

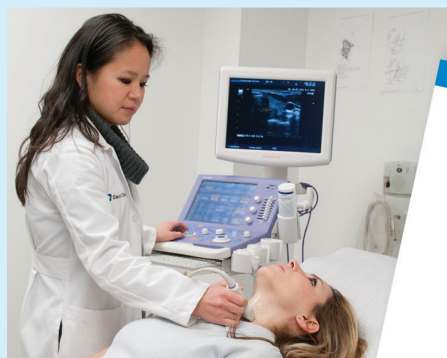Aspergillus is ubiquitous, so the significance of the finding depends on the patient’s symptoms, underlying lung condition, immune status, and radiologic findings.

Firas El-Baba, MD; Donovan Watza, PhD; Ayman O. Soubani, MD

CONTINUED ON PAGE 531

Upcoming Features

- Neuropsychiatric assessment of ICU survivors
- DXA in primary care
- Spontaneous coronary artery dissection



CLEVELAND
CLINIC
JOURNAL OF
MEDICINE

CONTINUED FROM PAGE 530

REVIEW

Ketogenic diets in the management of type 1 diabetes: Safe or safety concern? 547

A review of the potential risks and benefits for managing type 1 diabetes based on available evidence.

Lauren Anne Buehler, MD, MPH; Dawn Noe, RDN, LD, CDCES; Shannon Knapp, BSN, RN, CDCES; Diana Isaacs, Pharm D, CDCES; Kevin M. Pantalone, DO, ECNU, FACE

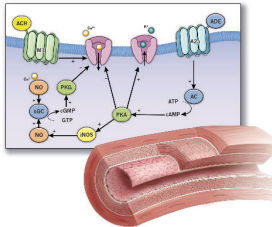
GUIDELINES TO PRACTICE

Risk-based guidelines: Redefining management of abnormal cervical cancer screening results 556

A shift from results-based to risk-based management, based on the patient's immediate and 5-year risks of grade 3 or higher cervical intraepithelial neoplasia.

Amy Wisner, MD, FAAFP; Jeffrey D. Quinlan, MD, FAAFP; Pelin Batur, MD, FACP, NCMP

REVIEW **CME MOC**



Coronary microvascular dysfunction: Considerations for diagnosis and treatment 561

A review of pathophysiology, considerations for invasive and noninvasive coronary function testing, management, and remaining knowledge gaps.

Benita Tjoe, MD; Lili Barsky, MD; Janet Wei, MD; Bruce Samuels, MD; Babak Azarbal, MD; C. Noel Bairey Merz, MD; Chrisandra Shufelt, MD, MS

SYMPTOMS TO DIAGNOSIS **CME MOC**

Rapid cognitive decline and myoclonus in a 52-year-old woman 572

Symptoms also included confusion, blank staring, blurred vision, incoordination of the extremities, decreased verbal communication, and holding her left hand in a fist.

William Gravley, MS; Caleb Murphy, MD, MBA; Chia-Dan Kang, MD; Badrunnisa Hanif, MD

DEPARTMENTS

CME Calendar 534

CME/MOC Instructions 584



Visit WWW.CCJM.ORG
Test your knowledge
of clinical topics

