

TABLE OF CONTENTS

FROM THE EDITOR

A perspective on discussing COVID-19 vaccines: Efficacy and adverse effects **644**

Physicians should be vigilant and open-minded regarding possible adverse reactions to the vaccines, and should take time to discuss the demonstrated efficacy of vaccines with patients.

Brian F. Mandell, MD, PhD

THE CLINICAL PICTURE

COVID-19 vaccine-induced cellulitis and myositis **648**

The day after receiving the second dose of the mRNA vaccine, redness and pain developed at the injection site, eventually involving the whole left arm and shoulder.

Sathishkumar Ramalingam, MD; Harkesh Arora, MD; Susan Lewis, MD; Kulothungan Gunasekaran, MD; Maheswari Muruganandam, MD; Sivakumar Nagaraju, MD; Priyesh Padmanabhan, MD

THE CLINICAL PICTURE

Metronidazole-induced encephalopathy: Symmetrical hyperintensity on imaging **651**

The diagnosis should be based on a combination of the patient's clinical history, laboratory findings, and imaging results.

Hiroki Matsuura, MD; Takashi Katayama, MD; Kentaro Deguchi, MD, PhD

THE CLINICAL PICTURE

Exanthem and enanthem with fever and dyspnea **653**

The patient presented with high fever, productive cough, dyspnea, generalized myalgias, conjunctivitis, and whitish elevations with an erythematous base on the buccal mucosa.

George D. Liatsos, MD, PhD; Emmanouil Koullias, MD

CONTINUED ON PAGE 643

Upcoming Features

- Discontinuing antidepressants
- Breast cancer risk evaluation
- Cardiac considerations in liver transplantation



CLEVELAND
CLINIC
JOURNAL OF
MEDICINE

CONTINUED FROM PAGE 642

COMMENTARY

Peyronie disease and erectile dysfunction: A potential new paradigm **661**

Viewing Peyronie disease as related to erectile dysfunction allows for the possibility of preventing the disease in patients with erectile insufficiency.

Drogo K. Montague, MD

GUIDELINES TO PRACTICE

Updated guidelines for immune thrombocytopenic purpura: Expanded management options **664**

The aim is to help practitioners decide on inpatient vs outpatient management, thresholds for initiating treatment, and options for second-line treatment in adults.

Sherwin DeSouza, MD; Dana Angelini, MD

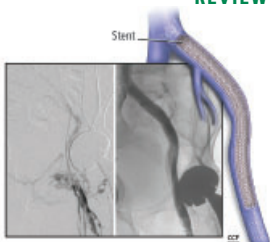
REVIEW

Neuropsychiatric assessment and management of the ICU survivor **669**

Post-intensive care syndrome occurs in 50% to 70% of ICU survivors. The authors examine various facets of this syndrome and emphasize the role of post-ICU recovery clinics.

Erin A. Dean, MD; Michelle Biehl, MD; Kathryn Bash, APRN, CNP; Jeremy Weleff, DO; Leopoldo Pozuelo, MD

REVIEW **CME | MOC**



Chronic venous outflow obstruction: An important cause of chronic venous disease **680**

A review of the key factors to consider in management of chronic venous outflow obstruction, and advice on how best to get patients the care they need.

Matthew Harris, MBBS, MRCS; Chung Sim Lim, MBBS, PhD, FRCS, FEBVS

REVIEW

Changing US trends in contraceptive choices **689**

The history and the pros and cons of depot medroxyprogesterone acetate and long-acting reversible contraceptives are examined.

Suneela Vegunta, MD, FACP, NCMP; Aakriti R. Carrubba, MD; Megan N. Wasson, DO, FACOG

DEPARTMENTS

CME Calendar **646**

Letters to the Editor **657**

Correction **659**

The following article contained an error: Williams S, Khan L, Licata AA. DXA and clinical challenges of fracture risk assessment in primary care. *Cleve Clin J Med* 2021; 88(11):615–622. doi:10.3949/ccjm.88a.20199

CME/MOC Instructions **696**