

TABLE OF CONTENTS

FROM THE EDITOR
Why we publish The Clinical Picture **69**
 Gout remains very common—and often undertreated.
 Brian F. Mandell, MD, PhD

THE CLINICAL PICTURE.....
Cutaneous digital papules **73**
 Tophi in the finger pads call for aggressive urate-lowering therapy.
 Hiroyuki Yano, MD; Mitsuyo Kinjo, MD, MPH

THE CLINICAL PICTURE.....
Pacemaker lead-induced venous thoracic outlet syndrome **75**
 Acute arm swelling and pain after an airline flight and a missed anticoagulant dose.
 Abhinav Sood, MBBS, MD; Daniel Benhuri, MD; Ujjwal Rastogi, MD; Ramesh M. Gowda, MD

THE CLINICAL PICTURE.....
Severe chemical pneumonitis from tetrahydrocannabinol ‘vaping’ and ‘dabbing’ **77**
 THC products have been implicated in an outbreak of lung injury.
 Alisha Kamboj, MD, MBA; Tony Kamel, MD; Martin Burbank, MD; Melisa Esposito, MD; Russell Shaen Harvey, MD

1-MINUTE CONSULT
How should you assess glycemic control if the hemoglobin A1c is inaccurate or uninterpretable? **81**
 Hemoglobin A1c is the standard but is not perfect. Alternatives are available.
 Wendy O. Henderson, MD; Mary H. Parker, PharmD, FASHP, FCCP, BCPS, BCCP; Bryan C. Batch, MD, MHS

SYMPTOMS TO DIAGNOSIS
Severe thrombocytopenia in a patient with otherwise asymptomatic COVID-19 **86**
 A young woman, seemingly healthy, presented with easy bruising.
 Lauren M. Granat, DO, MS; Achintya D. Singh, MBBS, MD; Matthew Cortese, MD, MPH; Vicente Velez, MD, FACP, FHM; Alan Lichtin, MD

CONTINUED ON PAGE 68

CONTINUED FROM PAGE 66

SYMPTOMS TO DIAGNOSIS

A 21-year-old woman with Ehlers-Danlos syndrome and persistent lightheadedness **93**

She has a long history of lightheadedness upon standing, and it is getting worse.

Raed Qarajeh, MD; Laith A. Derbas, MD; Mouin Abdallah, MD, MSc; Faraz Kureshi, MD, MSc

GUIDELINES TO PRACTICE

Reversal of direct oral anticoagulants: Highlights from the Anticoagulation Forum guideline **98**

Clear instructions on how to manage DOAC-associated bleeding.

Haeshik S. Gorr, MD; Lucy Yun Lu, PharmD, MS; Eric Hung, PharmD, CACP, AE-C

REVIEW

Oral immunotherapy: The answer to peanut allergy? **104**

Gradually increasing doses of the allergen induces tolerance.

Rachel M. Whitsel, APRN; Jaclyn A. Bjelac, MD; Ahila Subramanian, MD; Alice E. W. Hoyt, MD; Sandra J. Hong, MD

REVIEW

Cardiac surveillance for anti-HER2 chemotherapy **110**

A more focused approach is advocated.

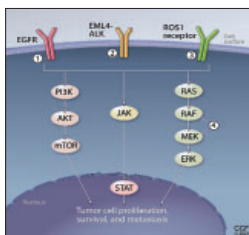
Patrick Collier, MD, PhD, FASE, FESC, FACC; Muzna Hussain, MD; Zoran B. Popovic, MD, PhD; Brian P. Griffin, MD

REVIEW **CME** **MOC**

Precision treatment for metastatic non-small cell lung cancer: A conceptual overview **117**

Targeted therapy has revolutionized treatment of patients with advanced solid tumors.

Tristan Lee, MD; Jeffrey M. Clarke, MD; Deepali Jain, MD; Sendhilnathan Ramalingam, MD; Vishal Vashistha, MD



DEPARTMENTS

CME Calendar **71**

2020 Reviewers **80**

CME/MOC Instructions **128**