

TABLE OF CONTENTS

FROM THE EDITOR

Awareness can prompt the search for clinical zebras **133**
 When do we look hard for uncommon causes of common symptoms?
 Brian F. Mandell, MD, PhD

THE CLINICAL PICTURE

**Median arcuate ligament syndrome:
 Incidental finding or real problem?** **140**
 A woman was admitted with pain in the epigastrium and right upper quadrant
 that radiated to the back, as well as nausea and dry heaves.
 Bayarmaa Mandzhieva, MD; Hammad Zafar, MD; Akriti Jain, MD; Manoucher Manoucheri, MD, FACP

EDITORIAL

**Median arcuate ligament syndrome:
 A clinical dilemma** **143**
 Patients with chronic abdominal pain can benefit from a multidisciplinary evaluation.
 John H. Rodriguez, MD, FACS

THE CLINICAL PICTURE

A cutaneous clue to HIV infection **145**
 A retired trucker presented with fever, cough, dyspnea, and a rash on his forehead.
 Stephen Chan, MD; Paul Aronowitz, MD

THE CLINICAL PICTURE

Not all wheezing is COPD **147**
 A missed diagnosis led to inappropriate referral for lung transplant.
 Vipul Patel, MD; Nikhil Madan, MD, FCCP

EDITORIAL

All that wheezes... **150**
 All that wheezes is not asthma, but it is airway obstruction of one kind or another.
 Aparna Bhat, MD; Rendell W. Ashton, MD

THE CLINICAL PICTURE

**Anterior interosseous nerve palsy caused
 by Parsonage-Turner syndrome** **155**
 A 58-year-old man presented with difficulty moving his left hand.
 Kosuke Ishizuka, MD; Kiyoshi Shikino, MD, PhD; Masatomi Ikusaka, MD, PhD

CONTINUED ON PAGE 132

CONTINUED FROM PAGE 130

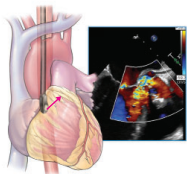
REVIEW CME MOC

**Vaccination in pregnancy:
A call to all providers for help** **157**

Vaccination in pregnancy is a public health priority that is often neglected.

Jonathan D. Emery, MD; Daniel Moussa, BS

REVIEW CME MOC



Imaging to evaluate suspected infective endocarditis **163**

What if echocardiographic findings are initially negative and the patient continues to have bacteremia?

Ikram-Ul Haq, MD; Iqraa Haq, BS; Brian Griffin, MD; Bo Xu, MD, FACC, FRACP, FASE

REVIEW CME MOC

**Male and female pattern hair loss:
Treatable and worth treating** **173**

Early recognition and treatment can help preserve as much hair as possible.

Nina L. Tamashunas, BS; Wilma F. Bergfeld, MD, FAAD

REVIEW CME MOC

**Frequently asked questions about managing cancer pain:
An update** **183**

Pain management can involve pharmacologic and nonpharmacologic therapies.

Renato V. Samala, MD, MHPE, FACP, FAAHPM; Ruth L. Lagman, MD, MPH, MBA, FACP, FAAHPM;
Sina Najafi, DO; Flannery Fielding, CNP, MSN

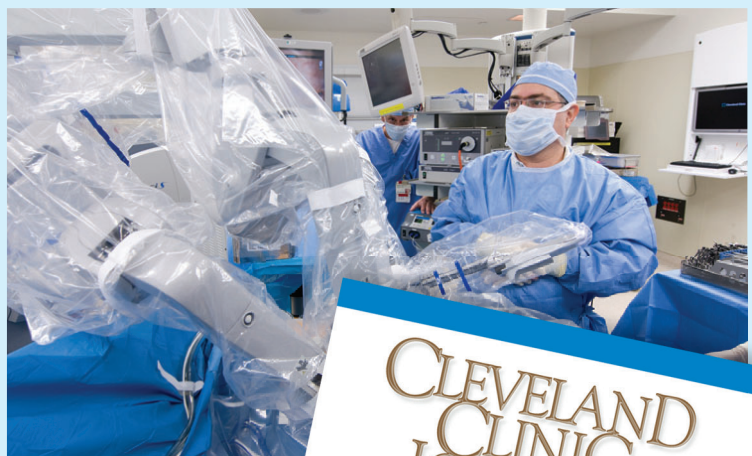DEPARTMENTS CME MOC

CME Calendar **136**

CME/MOC Instructions **192**

Upcoming Features

- **Dual antiplatelet therapy:
Personalize duration**
- **COVID-19 long-haulers:
Hard road ahead**
- **Quetiapine is not a sleeping pill**
- **Acute hip fracture:
Update on management**
- **CABG: When, why, and how?**



**CLEVELAND
CLINIC
JOURNAL OF
MEDICINE**