

TABLE OF CONTENTS

FROM THE EDITOR

Recognizing a retirement, and a calcium deposition syndrome 197

Personnel changes at *CCJM*, and underrecognition of calcium deposition in the cervical spine.

Brian F. Mandell, MD, PhD

THE CLINICAL PICTURE

Crowned dens syndrome: Caution about asymptomatic calcification 204

An 88-year-old man developed fever, headache, and posterior neck pain resistant to initial therapy.

Junki Mizumoto, MD

EDITORIAL

Calcium pyrophosphate deposition and crowned dens syndrome 206

Patients are typically over age 65, often with significant leukocytosis and dramatically elevated inflammatory markers.

Ann K. Rosenthal, MD

THE CLINICAL PICTURE

Tumoral calcinosis 208

A 47-year-old woman on peritoneal dialysis presented with dyspnea and hip pain.

Hiroyuki Yano, MD; Mitsuyo Kinjo, MD, MPH

THE CLINICAL PICTURE

Puffy hand syndrome 210

A 37-year-old man visited the rheumatology clinic for evaluation of swelling of his fingers and hands.

Soumya Chatterjee, MD, MS, FRCP

1-MINUTE CONSULT

Is it safe to start steroids at home for a COPD exacerbation after virtual assessment in the COVID-19 era? 213

Yes. Corticosteroids are beneficial, and virtual visits are appropriate, especially in this pandemic.

Achintya D. Singh, MBBS, MD; Agrima Mian, MD; James K. Stoller, MD, MS

CONTINUED ON PAGE 196

CONTINUED FROM PAGE 194

INTERPRETING KEY TRIALS

Update in perioperative cardiac medicine 2021 216

New light on preoperative assessment and on the need for anticoagulation.

Steven L. Cohn, MD, MACP, SFHM

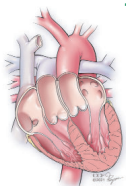
COMMENTARY

Our evolving understanding of primary aldosteronism 221

Current screening and confirmatory testing lack sensitivity and carry a poor negative predictive value.

Ali Mehdi, MD, MEd, FACP; Pratibha Rao, MD, MPH; George Thomas, MD

SYMPTOMS TO DIAGNOSIS



Pregnancy in a woman with congenitally corrected transposition of the great arteries 228

She presents with nausea and emesis 7 weeks after her last menstrual period.

Sarah A. Goldstein, MD; Lisa Sorenson, CNP; Jeffrey B. Chapa, MD; Richard A. Krasuski, MD

REVIEW **CME MOC**

Update on medical management of acute hip fracture 237

Emphasis is on prompt surgery, multimodal analgesia, and enhanced recovery pathways.

Lily Ackermann, MD, ScM; Eric S. Schwenk, MD; Yair Lev, MD; Howard Weitz, MD

DEPARTMENTS

CME Calendar 200

Correction 205

The following article contained an error: Tsushima Y, Lansang MC, Makin V. The role of SGLT-2 inhibitors in managing type 2 diabetes. *Cleve Clin J Med* 2021; 88(1):47–58. doi:10.3949/ccjm.88a.20088.

CME/MOC Instructions 248

Upcoming Features

- COVID-19 long-haul: A hard road back
- Bulimia nervosa
- CABG: Who, how, why
- Dual antiplatelet therapy: How long?
- Quetiapine is not a sleeping pill

