

THE CLINICAL PICTURE

Taylor Bullock, BS

Department of Dermatology,
Cleveland Clinic; Cleveland Clinic Lerner
College of Medicine of Case Western
Reserve University, Cleveland, OH

Daniel Michalik, MD

Department of Dermatology,
Cleveland Clinic, Cleveland, OH

Rashmi Unwala, MD

Department of Dermatology,
Cleveland Clinic, Cleveland, OH

John Anthony, MD

Department of Dermatology,
Cleveland Clinic, and Clinical Assistant
Professor, Cleveland Clinic Lerner College
of Medicine of Case Western Reserve
University, Cleveland, OH

Shedding light on subungual digital mucous cysts

**Transillumination
is a quick
and easy way
to diagnose DMC
and rule out
other subungual
masses**

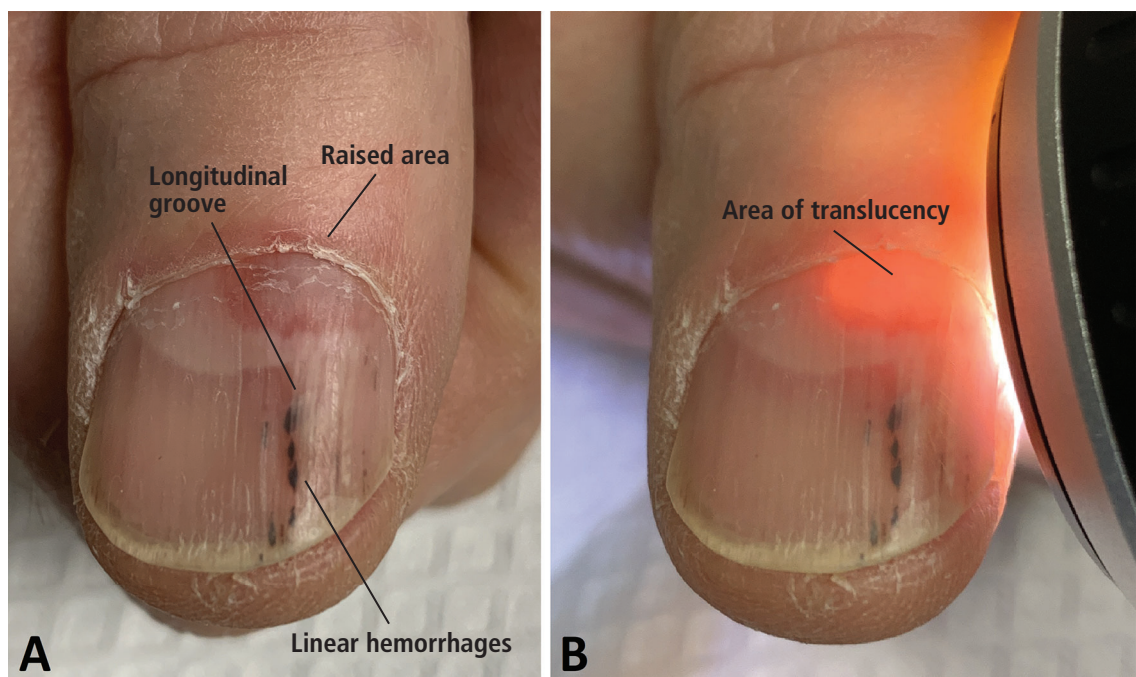


Figure 1. Subungual digital mucous cyst of the thumb nail: (A) longitudinal groove, distal linear hemorrhages, and a raised area at the proximal nail; and (B) a translucent area, 3 mm × 5 mm, beneath the nail matrix.

A 65-YEAR-OLD MAN presented with a thumbnail deformity that had been present for 3 months. He said he had no pain and no history of trauma to the nail.

Examination of the thumbnail revealed a longitudinal groove, distal linear hemorrhages, and a raised area at the proximal end that appeared to be a subungual nodule affecting the underside of the nail plate, and transillumination showed a translucent area 3 mm by 5 mm beneath the nail matrix (Figure 1). Examination of all other digits was unremarkable.

doi:10.3949/ccjm.88a.20125

Clinically, this presentation appeared to be consistent with a subungual digital mucous cyst (DMC) causing nail deformity due to compression of the nail matrix. To confirm the diagnosis, a sterile 22-gauge needle was used to drill through the nail plate into the translucent area. A copious amount of clear, gelatinous material, characteristic of a DMC, was expressed from the puncture site.

■ DIFFERENTIAL DIAGNOSIS

Longitudinal grooves in the nail bed can be caused by median nail dystrophy, trauma, compression of the nail matrix from tumors,

and physiologic furrows and ridges that are accentuated in diseases such as lichen planus and Darier disease. Tumors that can affect the nail matrix include various nail fibroma, DMC, pyogenic granuloma, glomus tumor, subungual exostosis, squamous cell carcinoma, and melanoma.¹

The translucency of this patient's subungual nodule was highly suggestive of a DMC, and the clear, gelatinous material expressed from the cyst confirmed it. In addition, a red lunula, as seen in our patient (**Figure 1**), is a common finding in subungual DMC.²

DIGITAL MUCOUS CYSTS

DMC, also known as myxoid pseudocyst or synovial cyst, commonly presents as a superficial, dome-shaped, shiny, cystic nodule located near the distal interphalangeal joint on the dorsum of the fingers. The cyst is commonly diagnosed clinically based on the appearance and the history of intermittent discharge of a mucoid substance.³ DMC is more common in people with osteoarthritis and in women.

While superficial DMC is common, the prevalence of subungual DMC is unknown, as few have been reported. The focal collec-

tion of fluid in DMC lacks a cystic lining, so DMC is not a true cyst. DMC can cause nail deformities by compressing nail matrix cells, most commonly proximal and superficial to the proximal nail fold.¹

Subungual DMC is much more difficult to diagnose than its superficial counterpart, not only because it is less accessible, but also because it lacks the characteristic appearance of superficial DMC and does not cause intermittent mucinous discharge.³ Though DMC is commonly asymptomatic when left untreated, subungual DMC most often requires nail avulsion and surgery to rule out other subungual masses, including malignancies.⁴

Transillumination is a quick and easy way to diagnose DMC and rule out other subungual masses, as seen in this case. The finding of a translucent cyst can spare the patient from undergoing nail avulsion and surgery. When evaluating subungual masses, all clinicians should be aware of the utility of transillumination in the diagnosis of subungual DMC. ■

DISCLOSURES

The authors report no relevant financial relationships which, in the context of their contributions, could be perceived as a potential conflict of interest.

REFERENCES

1. **Patterson J.** Cutaneous mucinosis. In: *Weedon's Skin Pathology*. 5th ed. New York: Elsevier; 2021:448.
2. **de Berker D, Goettman S, Baran R.** Subungual myxoid cysts: clinical manifestations and response to therapy. *J Am Acad Dermatol* 2002; 46(3):394–398. doi:10.1067/mjd.2002.119652
3. **Willard KJ, Cappel MA, Kozin SH, Abzug JM.** Benign subungual tumors. *J Hand Surg Am* 2012; 37(6):1276–1286. doi:10.1016/j.jhsa.2012.04.001
4. **Jabbour S, Kechichian E, Haber R, Tomb R, Nasr M.** Management of digital mucous cysts: a systematic review and treatment algorithm. *Int J Dermatol* 2017; 56(7):701–708. doi:10.1111/ijd.13583

Address: Taylor Bullock, BS, Department of Dermatology, Cleveland Clinic, 9500 Euclid Avenue, Cleveland, OH 44195; bulloct2@ccf.org