

# TABLE OF CONTENTS

FROM THE EDITOR .....

**Sometimes the look is worth the walk 4**

We do not routinely look at blood smears today. The need for expediency and efficiency limit the time spent on activities with a low yield for influencing care. And yet, for some conditions in some patients, going back to the basics can be clinically rewarding, and even memorable.

Brian F. Mandell, MD, PhD

THE CLINICAL PICTURE.....

**Megaloblastic anemia due to vitamin B<sub>12</sub> deficiency 8**

The 75-year-old patient presenting with altered mental status and pancytopenia had a history of peptic ulcer disease and subtotal gastrectomy.

Nellowe Candelario, MD; Catherine Klein, MD

THE CLINICAL PICTURE.....

**A large, painless bulla on the right foot 10**

A patient with a history of type 2 diabetes and diabetic neuropathy had a hemoglobin A1c of 10.3% at presentation.

Jorge Camilo Mora, MD, MPH; Amalia Galindez, MD, FACP

REVIEW .....

**Clinical impact of 2020 American Heart Association statement on menopause and cardiovascular disease risk 13**

The statement supports the notion that the transition of menopause itself leads to increased cardiovascular risk and mortality.

Tara K. Iyer, MD, NCMP; Heather Hirsch, MD, MS, NCMP

CONTINUED ON PAGE 3

## Upcoming Features

- Evaluating breast cancer risk
- When is testing needed for penicillin allergy?
- Anemia of chronic kidney disease



CLEVELAND  
CLINIC  
JOURNAL OF  
MEDICINE

CONTINUED FROM PAGE 2

**REVIEW** .....

**Discontinuing antidepressants: Pearls and pitfalls** **18**

To date, no formal schedule for tapering antidepressants has been validated. The maxim “slower is better” applies.

Samantha J. Zwiebel, MD; Adele C. Viguera, MD

**SYMPTOMS TO DIAGNOSIS** ..... **CME MOC**

**A painful mass in the jaw** **27**

The patient presented with a painful mass in the left side of her jaw, headache, lockjaw, painful swallowing, night sweats, and unintentional weight loss.

Kanishka G. Patel, MD; Jasmine C. Huynh, MD; James Liu, MD; Paul Aronowitz, MD; May Cho, MD

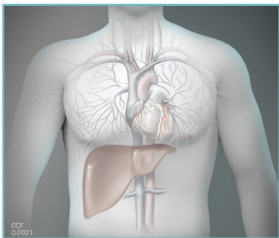
**MEDICAL GRAND ROUNDS** .....

**Evaluation and management of orthostatic hypotension: Limited data, limitless opportunity** **36**

Orthostatic hypotension is common and can have serious consequences. The author offers a systematic approach to evaluation and management.

Aldo J. Peixoto, MD

**REVIEW** .....



**Cardiac considerations in liver transplantation** **46**

Today’s transplant patients are older and more likely to have cardiac comorbidities, and effects of advanced liver disease on the circulatory system pose challenges in perioperative management.

Vikram Sharma, MD, MD(Res); Cerise Kleb, MD; Chirag Sheth, MD; Beni Rai Verma, MD; Vardhmaan Jain, MD; Ruchi Sharma, MD, MS; Parth Parikh, MD; Jacek Cywinski, MD; K. V. Narayanan Menon, MD, FAASLD; Jamak Modaresi Esfeh, MD; Bijan Egtesad, MD; Cristiano Quintini, MD; Teresa Diago Uso, MD; Michael Z. Y. Tong, MD; Ravi Nair, MD; Ajay Bhargava, MD; Maan Fares, MD

**DEPARTMENTS** .....

**CME Calendar** **6**

**CME/MOC Instructions** **56**



**Visit [WWW.CCJM.ORG](http://WWW.CCJM.ORG)  
Test your knowledge  
of clinical topics**

