

**Anam Rizvi, MD**

Division of Gastroenterology and Hepatology, North Shore University Hospital—Long Island Jewish Medical Center, Zucker School of Medicine at Hofstra/Northwell, Northwell Health System, Manhasset, NY

**Amrita Sethi, MD**

Associate Professor of Medicine, Director of Interventional Endoscopy, Division of Digestive and Liver Diseases, Department of Medicine, Columbia University, New York, NY

**John Poneris, MD**

Associate Professor of Medicine, Division of Digestive and Liver Diseases, Department of Medicine, Columbia University, New York, NY

**Kavel H. Visrodia, MD**

Assistant Professor of Medicine, Division of Digestive and Liver Diseases, Department of Medicine, Columbia University, New York, NY

# Q: Does incidentally detected common bile duct dilation need evaluation?

**A:** It depends. If dilation of the common bile duct is detected incidentally with ultrasonography or computed tomography (CT) and the patient has clinical signs (eg, jaundice, pruritus, fever, weight loss), concerning laboratory test results (eg, elevated total bilirubin), or additional concerning imaging findings (Table 1), then further evaluation is indicated with magnetic resonance cholangiopancreatography (MRCP) with contrast, endoscopic ultrasonography (EUS), or endoscopic retrograde cholangiopancreatography (ERCP). If the patient does not have clinical signs or concerning laboratory test results but does have risk factors for nonobstructive dilation such as age over 60, previous cholecystectomy, or opioid use, then the dilation is likely benign, and further investigation is not warranted.

**A common bile duct measuring 7 mm or greater is generally accepted as the dilation cutoff for clinical and research purposes**

To avoid unnecessary testing and imaging, a patient-centered approach integrating the clinical history, liver biochemistries, and knowledge of the diagnostic yield of further testing can help clinicians determine appropriate management for incidentally detected common bile duct dilation.

**■ WHAT CONSTITUTES BILE DUCT DILATION?**

There is no absolute measurement that defines common bile duct dilation, but a dilation of 7 mm or greater is generally accepted as the cutoff for clinical and research purposes. It is important to note that

TABLE 1

**Clinical considerations and red flags for incidental bile duct dilation**

**Clinical signs of bile obstruction**

- Jaundice
- Steatorrhea
- Acholic stools
- Dark urine
- Pruritus
- Weight loss (concern for malignancy)
- Fever, right upper quadrant abdominal pain, and jaundice (concern for ascending cholangitis)

**Relevant findings on laboratory testing**

Elevation of any of the following:

- Total or direct serum bilirubin
- Alkaline phosphatase
- Aspartate aminotransferase
- Alanine aminotransferase

**Abnormal imaging findings**

- Concurrently dilated pancreatic duct (“double-duct” sign)
- Intraductal stone or lesion
- Intrahepatic duct dilation
- Moderate to severe extrahepatic duct dilation (≥ 10 mm)
- Abrupt cutoff in common bile duct dilation
- New or progressive dilation compared with prior imaging

measurement ranges for dilation vary based on the imaging modality, site of measurement along the duct, and patient factors (eg, age, history of cholecystectomy). The upper limit of normal for common bile duct diameter is 6 to 8 mm when measured with transabdominal ultrasonography, and 8 to 10 mm with CT.<sup>1</sup> To adjust for age, adding 1 mm to the mea-

doi:10.3949/cjcm.89a.21029

surement per decade of life after age 60 or 0.4 mm for each decade of life has been proposed, although the evidence varies.<sup>1</sup> After cholecystectomy, asymptomatic common bile duct dilation of up to 10 mm has been reported to be within normal range.<sup>2</sup> Given the challenges to defining specific dilation values, the decision to pursue further diagnostic testing should be based on the likelihood of underlying obstructive vs nonobstructive causes.

### Obstructive vs nonobstructive causes

Obstructive causes of common bile duct dilation include choledocholithiasis, malignancy (eg, pancreatic cancer, cholangiocarcinoma, ampullary carcinoma), extrinsic compression (eg, Mirizzi syndrome, lymphadenopathy, fluid collections), chronic pancreatitis stricture, periampullary diverticulum, primary sclerosing cholangitis, papillary stenosis, and parasitic worm infection (uncommon in the United States).<sup>1,3</sup> A nonobstructive dilation can be related to age over 60, previous cholecystectomy (or other bile surgery), and opioid use,<sup>4</sup> and dilation in patients with these risk factors is considered benign.

Rarely, bile duct dilation is caused by cysts (eg, choledochal cysts),<sup>5</sup> which typically have a distinct appearance on imaging.

### CLINICAL EVALUATION

Specific elements of the patient's history, physical examination, and biochemical markers can help determine if biliary obstruction warrants further investigation (**Table 1**). Clinical symptoms such as jaundice, steatorrhea, acholic stools, dark urine, pruritus, and weight loss can reflect obstructive causes, which may include malignancy. The combination of fever, abdominal pain, and jaundice (Charcot triad) suggests ascending cholangitis, which occurs more commonly with choledocholithiasis than with malignancy in the absence of a previous biliary procedure such as ERCP.<sup>1</sup> Acute onset of symptoms including pain is typical of choledocholithiasis, whereas gradual weight loss and jaundice (often painless) suggest a malignant process.

Abnormal liver biochemistry results including elevation of total or direct serum bilirubin, alkaline phosphatase, aspartate aminotransferase, and alanine aminotransferase can indicate an obstructive cause and should be evaluated. To some degree, these levels can be elevated in the setting of common bile duct obstruction, depending on the cause, extent, and chronicity of disease. Moreover, imaging with EUS is more likely to reveal a cause for dilated common

bile duct in patients with elevated liver biochemistries than in those without (53% vs 6%), highlighting the importance of testing for these abnormalities.<sup>6</sup> Although this article focuses on evaluating incidental common bile duct dilation, if abnormal liver biochemistries persist after an appropriate workup for bile duct dilation (see discussion below), further assessment is needed in accordance with published guidelines<sup>7</sup> and in consultation with gastroenterology and hepatology specialists.

### Given the challenges to defining specific dilation values, further diagnostic investigation is primarily based on obstructive vs nonobstructive causes

If there are no concerning clinical or biochemical findings for obstruction and there is no explanation for nonobstructive dilation such as older age, previous cholecystectomy, or opioid use, imaging should be done to exclude features suggestive of an infrequently encountered subclinical or impending obstructive process. These include a concurrently dilated pancreatic duct (the “double-duct sign”), which could indicate a pancreatic or ampullary tumor; an appreciable intraductal biliary stone or lesion suggesting choledocholithiasis; intrahepatic bile duct dilation ( $\geq 1$ –2 mm); moderate to severe extrahepatic bile duct dilation ( $\geq 10$  mm), or an abrupt cutoff of the common bile duct dilation.<sup>1,8</sup> If available, prior imaging (including an intraoperative cholangiogram performed during cholecystectomy) should also be reviewed as a new or progressive dilation may be more concerning than a chronic stable dilation.

In the absence of the above findings, mild ductal dilation may be benign, especially in patients who are over age 60, have undergone cholecystectomy, or use opioids, and does not warrant further evaluation. Studies have shown that further diagnostic testing of incidentally found asymptomatic ductal dilations without clinical or biochemical abnormalities has very low diagnostic yield,<sup>9</sup> but it is a potential area for research.<sup>10</sup>

### IMAGING OPTIONS FOR WORKUP

If a common bile duct dilation is identified and the decision is made to pursue further workup, the next step is to determine which imaging modality to use. The most commonly used options are described below.

### MRCP with contrast

MRCP with contrast detects the cause of bile duct obstruction more accurately than transabdominal ultrasonography and CT. Its sensitivity for detecting choledocholithiasis is 92% and its specificity is 97%, depending on stone size; the sensitivity for malignancy is 88%, and the specificity is 95%.<sup>1</sup> Because MRCP is noninvasive and does not require ionizing radiation, it can be a useful first tool for evaluation of bile duct dilation. However, its reported accuracy in distinguishing benign from malignant causes of obstruction varies widely, from 30% to 98%.<sup>1</sup> The cost of the procedure is high compared with transabdominal ultrasonography and CT. In addition, some patients may suffer from severe claustrophobia or have difficulty holding their breath or lying still during the scan, potentially causing motion artifact and decreasing sensitivity of the imaging for smaller stones.<sup>1</sup>

### Endoscopic ultrasonography

EUS provides high-resolution images of the pancreaticobiliary system, detecting choledocholithiasis with greater than 90% sensitivity and up to 100% specificity, and pancreatic neoplasms such as carcinoma and cysts with sensitivity of 90% or greater.<sup>1</sup> If abnormalities are identified, diagnostic biopsy via fine-needle aspiration or fine-needle (core) biopsy can be performed as well. Visualization can be limited by pancreatic calcifications, inflammation from acute pancreatitis, altered anatomy of the stomach and proximal duodenum, and pneumobilia (most commonly resulting from previous instrumentation).<sup>1</sup> Due to the cost and the need for sedation, EUS is typically performed in patients with a high probability of bile duct obstruction and with an anticipated need for tissue acquisition or intervention, or in patients for whom MRCP with contrast is not possible or contraindicated.

### Cholangiopancreatography

ERCP is primarily a therapeutic intervention when obstruction is probable (ie, there are signs of ascending cholangitis) rather than for purely diagnostic purposes, and it is typically preferred over percutaneous or surgical methods.<sup>11</sup> This shift toward its use as a therapeutic modality is partly due to advances in noninvasive imaging (MRCP with contrast, EUS) that obviate the need for diagnostic ERCP and its related adverse events such as post-ERCP pancreatitis. In patients with bile duct obstruction, ERCP can provide decompression via sphincterotomy, stone extraction, or stent placement. If indicated, it can be

performed immediately after EUS during a single session of anesthesia.<sup>12</sup>

## In patients with bile duct obstruction, ERCP can provide decompression via sphincterotomy, stone extraction, or stent placement

### CLINICAL APPROACH TO THE EVALUATION

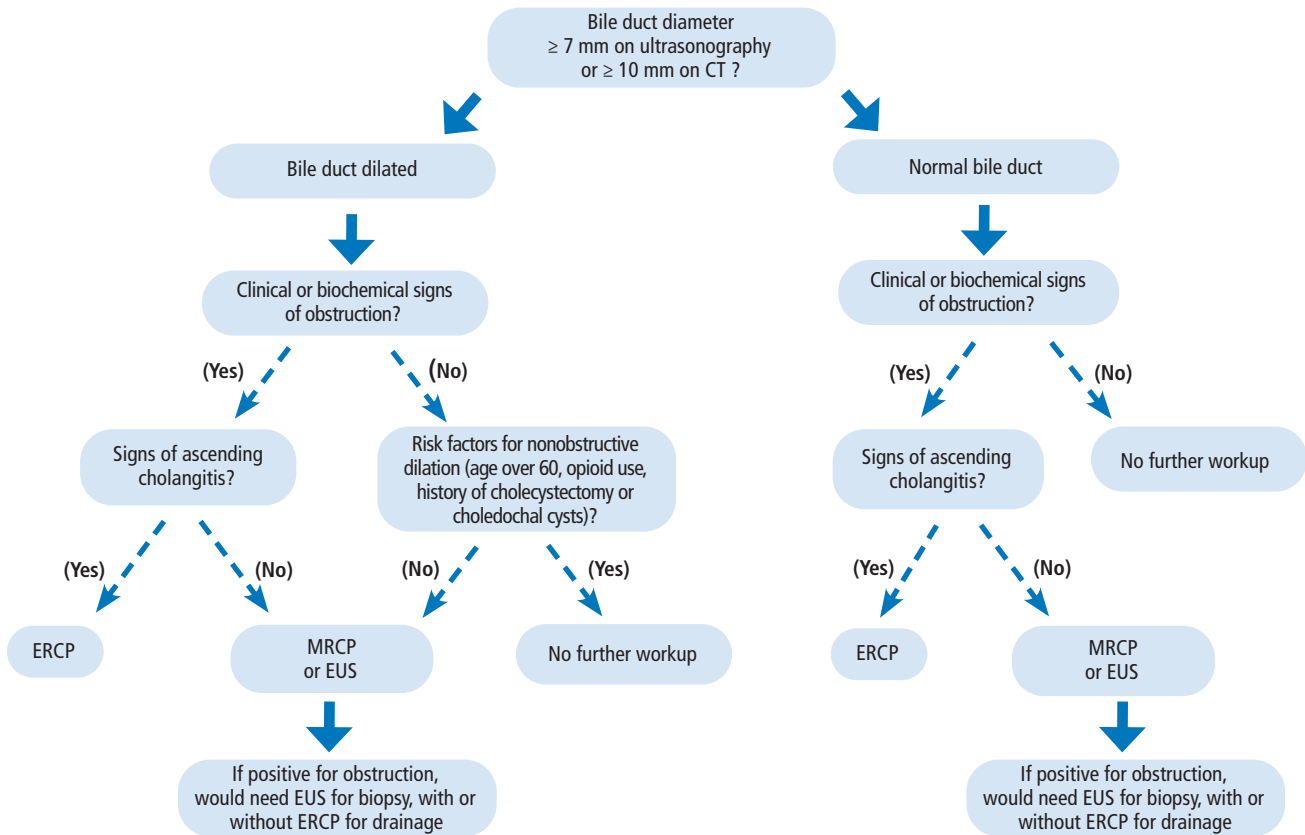
For a patient with potential incidental bile duct dilation, there are 4 general clinical decision-making pathways, as follows (Figure 1)<sup>1,3</sup>:

- Common bile duct dilation (ie,  $\geq 7$  mm on ultrasonography or  $\geq 10$  mm on CT) with clinical or biochemical features of obstruction warrants further investigation. ERCP is the initial choice if there are signs of ascending cholangitis. If there are no signs of ascending cholangitis, MRCP with contrast or EUS is indicated, and if these imaging results are positive for obstruction, EUS for biopsy with or without ERCP for drainage is needed.
- If there is dilation but no clinical or biochemical signs of obstruction, and if the patient has risk factors for nonobstructive dilation (eg, older age, previous cholecystectomy, opioid use), no further workup is warranted. But if the patient has no risk factors for nonobstructive dilation, then pursue MRCP with contrast or EUS.
- If the common bile duct diameter is normal (ie,  $< 7$  mm on ultrasonography or  $< 10$  mm on CT) but there are clinical or biochemical signs of obstruction, further evaluation is warranted. If there are signs of ascending cholangitis, an ERCP is indicated. If there are no signs of ascending cholangitis, MRCP with contrast or EUS is indicated. If either imaging test shows an obstruction, EUS for biopsy with or without ERCP for drainage is needed.
- If the bile duct diameter is normal and there are no clinical or biochemical characteristics of obstruction, further evaluation is not indicated. If EUS or ERCP is warranted or if there is uncertainty regarding the workup of bile duct dilation, the patient should be referred to a gastroenterologist.

### TAKE-HOME POINTS

Once identified, incidental common bile duct dilation can be categorized as nonobstructive or obstructive. Clinical, biochemical, and imaging findings should guide the decision-making regarding further evaluation or intervention. MRCP with contrast and

## COMMON BILE DUCT DILATION



**FIGURE 1.** Clinical approach to incidental bile duct dilation.

CT = computed tomography; ERCP = endoscopic retrograde cholangiopancreatography; EUS = endoscopic ultrasonography; MRCP = magnetic resonance cholangiopancreatography

Based on information in reference 1.

EUS can provide an accurate and minimally invasive diagnostic evaluation, while ERCP is best reserved for patients who require therapeutic intervention. ■

### DISCLOSURES

Dr. Sethi has disclosed consulting for Boston Scientific, Fujifilm, Interscope, Medtronic, and Olympus America. The other authors report no relevant financial relationships which, in the context of their contributions, could be perceived as a potential conflict of interest.

## REFERENCES

1. Das KK, Kochman ML. Dilated bile duct and pneumobilia. In: Baron TH, Kozarek RA, Carr-Locke DL, editors. ERCP. 3rd ed. Philadelphia, PA: Elsevier; 2019.
2. Park SM, Kim WS, Bae IH, et al. Common bile duct dilatation after cholecystectomy: a one-year prospective study. *J Korean Surg Soc* 2012; 83(2):97–101. doi:10.4174/jkss.2012.83.2.97
3. Holm AN, Gerke H. What should be done with a dilated bile duct? *Curr Gastroenterol Rep* 2010; 12(2):150–156. doi:10.1007/s11894-010-0094-3
4. Barakat MT, Banerjee S. Incidental biliary dilation in the era of the opiate epidemic: high prevalence of biliary dilation in opiate users evaluated in the emergency department. *World J Hepatol* 2020; 12(12):1289–1298. doi:10.4254/wjh.v12.i12.1289
5. Gigot JF, Nagorney DM, Farnell MB, Moir C, Ilstrup D. Bile duct cysts: a changing spectrum of presentation. *J Hep Bil Pancr Surg* 1996; 3(4):405–411. qqq
6. Malik S, Kaushik N, Khalid A, et al. EUS yield in evaluating biliary dilatation in patients with normal serum liver enzymes. *Dig Dis Sci* 2007; 52(2):508–512. doi:10.1007/s10620-006-9582-6
7. Kwo PY, Cohen SM, Lim JK. ACG clinical guideline: evaluation of abnormal liver chemistries. *Am J Gastroenterol* 2017; 112(1):18–35. doi:10.1038/ajg.2016.517
8. Smith I, Monkemuller K, Wilcox CM. Incidentally identified common bile duct dilatation: a systematic review of evaluation, causes, and outcome. *J Clin Gastroenterol* 2015; 49(10):810–815. doi:10.1097/MCG.0000000000000394
9. Chhoda A, Dawod S, Grimshaw A, Gunderson C, Mahadev S. Evaluation of diagnostic yield of EUS among patients with asymptomatic common bile duct dilation: systematic review and meta-analysis. *Gastrointest Endosc* 2021; 94(5):890–901.e8. doi:10.1016/j.gie.2021.07.002
10. Kim JE, Lee JK, Lee KT, et al. The clinical significance of common bile-duct dilatation in patients without biliary symptoms or causative lesions on ultrasonography. *Endoscopy* 2001; 33(6):495–500. doi:10.1055/s-2001-15088
11. ASGE Standards of Practice Committee, Chathadi KV, Chandrasekhara V, et al. The role of ERCP in benign diseases of the biliary tract. *Gastrointest Endosc* 2015; 81(4):795–803. doi:10.1016/j.gie.2014.11.019
12. Ascunce G, Ribeiro A, Rocha-Lima C, et al. Single-session endoscopic ultrasonography and endoscopic retrograde cholangiopancreatography for evaluation of pancreaticobiliary disorders. *Surg Endosc* 2010; 24(6):1447–1450. doi:10.1007/s00464-009-0798-3

Address: Kavel Visrodia, MD, Division of Digestive and Liver Diseases, Department of Medicine, Columbia University, 161 Fort Washington Avenue, 8th Floor, Suite 852A, New York, NY 10032; khv2105@cumc.columbia.edu