

# TABLE OF CONTENTS

FROM THE EDITOR

**Nontuberculous mycobacterial musculoskeletal infections: Recognizable, when suspected** **355**

Two articles in this issue offer valuable insight into when to suspect these infections in patients who present with swollen, indurated, peripheral soft-tissue structures.

Brian F. Mandell, MD, PhD

THE CLINICAL PICTURE

**Dactylitis from *Mycobacterium intracellulare* infection** **360**

A 69-year-old man presents with 6 months of progressive swelling of the right middle finger, with no systemic symptoms.

Hayato Shimizu, MD; Takumi Hashimura, MD; Hiroaki Nishioka, MD, PhD

REVIEW

CME MOC

**Which ICU patients need stress ulcer prophylaxis?** **363**

An examination of the controversy surrounding stress ulcer prophylaxis in critically ill patients, with guidance for its appropriate use in this setting.

Mariam Saeed, MD; Stephanie Bass, PharmD; Neal F. Chaisson, MD

THE CLINICAL PICTURE

**Unraveling a challenging diagnosis: Role of a TNF inhibitor** **368**

Painful swelling of the dorsum of the right hand had been diagnosed as chronic cutaneous sarcoidosis with tenosynovitis, treated unsuccessfully with prednisone and methotrexate.

Soumya Chatterjee, MD, MS, FRCP, FACP, FACR

THE CLINICAL PICTURE

**Mondor disease of the breast** **371**

A 43-year-old woman had 2 weeks of pain and skin tightness over the right breast. Ultrasonography revealed a noncompressible, dilated, subcutaneous vein without flow.

Toshiyuki Yamaguchi, MD

CONTINUED ON PAGE 350

## Upcoming Features

- GLP-1 receptor agonists in type 2 diabetes
- Exercise restriction in patients with pericarditis
- Risk-reducing mastectomy: Patient selection and timing



CLEVELAND  
CLINIC  
JOURNAL OF  
MEDICINE

REVIEW .....

**Women’s health update: A literature review impacting primary care 373**

The authors review cardiovascular disease, bone health, breast cancer risk, cervical cancer prevention, postpartum depression, pelvic pain, and emergency contraception.

Brigid M. Dolan, MD, MEd; Sarah Merriam, MD, MS; Christine A. Prifti, MD; Judith M. Walsh, MD, MPH

SYMPTOMS TO DIAGNOSIS .....

**Acute anxiety and tachycardia in a hospitalized 59-year-old woman 383**

The patient presented with neck pain, painful swallowing, headache, and fever. She had contracted lymphoproliferative disease after liver transplant. She had stage 3 chronic kidney disease.

Andres I. Applewhite, MD; Fernando F. Stancampiano, MD; Dana M. Harris, MD; Victor Bernet, MD; Joseph G. Cernigliaro, MD; Jose R. Valery, MD

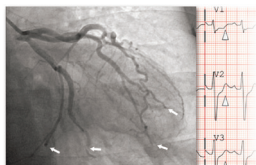
REVIEW .....

**Metastatic bone disease: Early referral for multidisciplinary care 393**

A lack of awareness and recognition of symptoms continues to delay referral to specialist teams. The authors provide guidance for early diagnosis and referral.

Amir Hossain Gahanbani Ardakani, BSc, MBBS; Martina Faimali, MBBS, FRCS (Tr&Orth); Lukas Nystrom, MD; Nathan Mesko, MD; Muntzer Mughal, MBChB, ChM, FRCS; Howard Ware, MBBS, FRCS (Tr&Orth); Panagiotis Gikas, BSc, MBBS Hons, MD (Res), PhD, FRCS (Tr&Orth)

SYMPTOMS TO DIAGNOSIS .....



**An unexpected turn:  
A 71-year-old man with myocardial infarction 401**

The patient’s temperature was elevated, pulse rate 98 beats per minute, respiratory rate 16 breaths per minute, and blood pressure 100/60 mm Hg. Cardiac and pulmonary examinations were normal.

Smitha Ganeshan, MD, MBA; Benjamin Kelemen, MD; Gurpreet Dhaliwal, MD; Lucas Zier, MD, MS

DEPARTMENTS .....

**CME Calendar 358**

**CME/MOC Instructions 408**