

Hayato Shimizu, MD

Department of General Internal Medicine,
Kobe City Medical Center General Hospital,
Kobe, Hyogo, Japan

Takumi Hashimura, MD

Department of Orthopaedic Surgery, Kobe
City Medical Center General Hospital,
Kobe, Hyogo, Japan

Hiroaki Nishioka, MD, PhD

Department of General Internal Medicine,
Kobe City Medical Center General Hospital,
Kobe, Hyogo, Japan

Dactylitis from *Mycobacterium intracellulare* infection

A 69-YEAR-OLD MAN WAS REFERRED to our hospital with a 6-month history of progressive swelling in the right middle finger without systemic symptoms. There was no previous trauma or surgery to the finger. The patient had previously been diagnosed with rheumatoid arthritis treated with methotrexate and hypertension treated with cilnidipine (a calcium channel blocker).

Physical examination revealed non-tender, sausage-like swelling of the right middle finger (**Figure 1**) with no nail abnormality or rash suggestive of psoriasis. Laboratory testing revealed a white blood cell count of $5.4 \times 10^9/L$ (reference range 4.5–10.9) and a C-reactive protein level of 0.07 mg/dL (reference range 0.0–0.5). Hand radiography revealed soft-tissue swelling of the right middle finger without joint erosions or periostitis.

Dactylitis is rare in patients with rheumatoid arthritis

Magnetic resonance imaging (MRI) revealed soft-tissue swelling and thickening around the digital flexor tendon showing high intensity on short time inversion recovery (**Figure 2A**), and ultrasonography revealed low echoic area and power Doppler signals around the digital flexor tendon (**Figure 2B**), consistent with inflammation. Dactylitis is rare in patients with rheumatoid arthritis, and thus, the examination differed from that of typical rheumatoid arthritis. The patient did not show signs of other inflammatory diseases associated with dactylitis. We performed a biopsy around the digital flexor tendon of the affected finger to exclude infection.

Histology revealed exudative synovitis with lym-

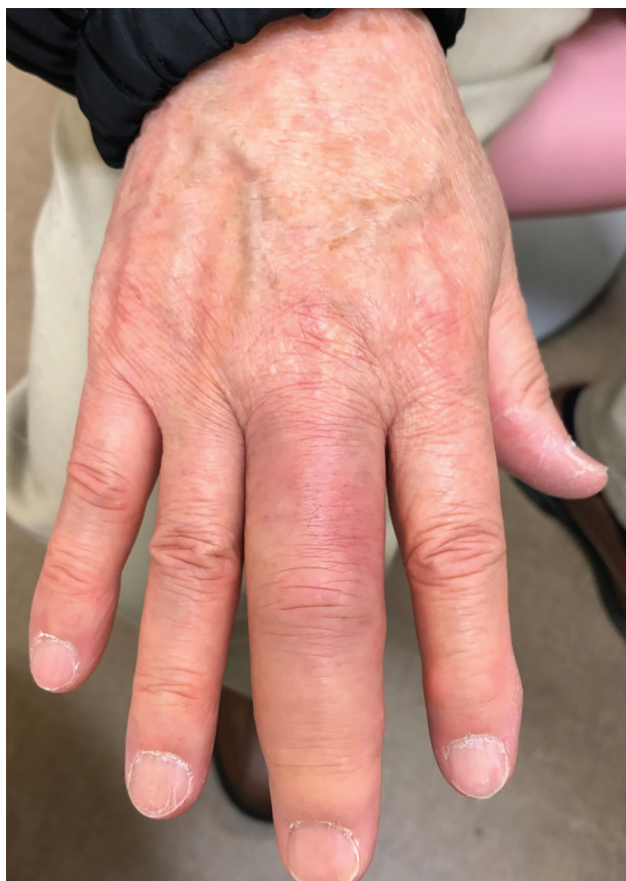

Figure 1. At presentation, the patient's right middle finger was swollen, with a sausage-like appearance.

phocyte and plasma cell infiltration. Tissue culture initially yielded no bacteria; however, mycobacterial culture was positive for *Mycobacterium intracellulare*. The patient was diagnosed with dactylitis due to *M intracellulare* infection and treated with rifampin, ethambutol, and clarithromycin. The finger swelling markedly improved over 6 months.

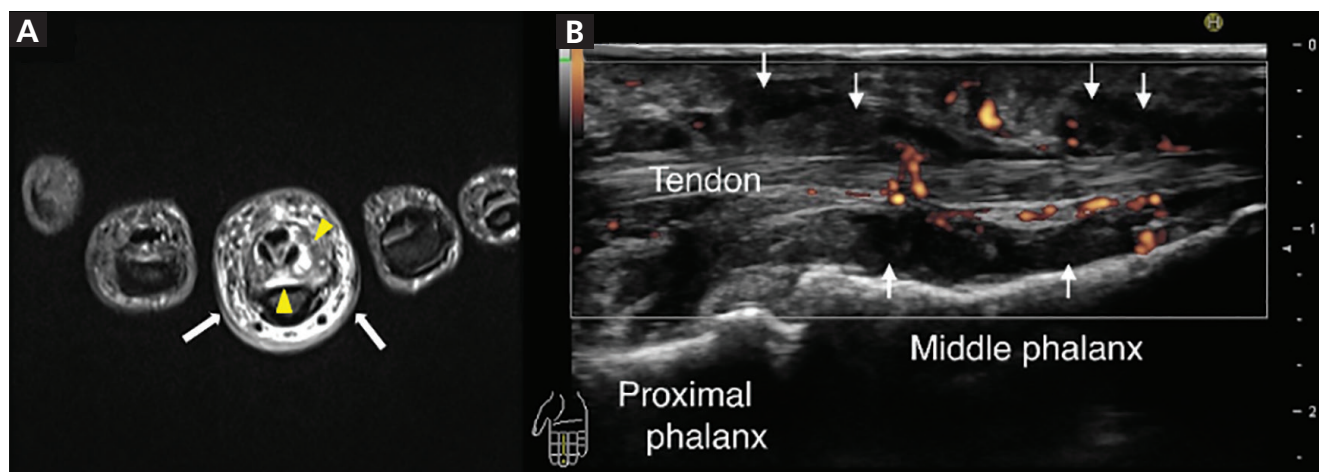


Figure 2. (A) Axial magnetic resonance imaging set on short time inversion recovery showed a high signal around the digital flexor tendon of the right middle finger (yellow arrowheads) and in the subcutaneous tissue (white arrows). (B) Ultrasonography of the right middle finger (sagittal view) showed a low echoic area (white arrows) and power Doppler signals around the digital flexor tendon.

■ DACTYLITIS

Dactylitis is the inflammation of a finger or toe with swelling of the entire digit rather than just a knuckle joint.¹ Dactylitis can be classified based on the involved tissue of the digit, ie, bone only, bone and soft tissue, or soft tissue only. In addition, dactylitis may be classified according to the etiology as noninflammatory, inflammatory infectious, and inflammatory noninfectious.¹

Spondyloarthritis dactylitis has been described as sausage-like in appearance and involves pain and swelling of the fingers or toes, mostly along the flexor tendons.¹ Related disorders include psoriatic arthritis, ankylosing spondylitis, enteropathic arthritis, and reactive arthritis.¹

MRI and ultrasonography²⁻⁴ show an increase in the volar bone-to-skin distance in dactylitic fingers that can be due to synovial thickening around the flexor tendons and may also show fluid collection in the tendon sheaths, indicating flexor tenosynovitis and adjacent soft-tissue swelling with small-joint synovitis.²⁻⁴

Although rare, tuberculous dactylitis can be the result of extrapulmonary tuberculosis with involvement of the digit and soft tissue.⁵ Radiographs typically show bone erosion (spina ventosa),⁶ and MRI shows that the lesion often extends to the soft tissue of the digit through cortical defects forming a sinus tract.⁵

The differential diagnosis of dactylitis includes syphilitic dactylitis, a manifestation of congenital

syphilis; sarcoid dactylitis, with infiltration of the phalangeal soft tissue by noncaseating granulomas; sickle cell dactylitis, or “hand-foot syndrome,” associated with infarction of bone marrow, usually in children; and reactive distal dactylitis of the anterior fat pad, mostly due to group A beta-hemolytic streptococci.¹ Dactylitis can also be associated with gout, resulting from deposition of monosodium urate crystals in the soft tissue of the involved digits¹ and from infection.

■ MYCOBACTERIUM INTRACELLULARE INFECTION OF A FINGER

Nontuberculous mycobacteria (NTM) cause pulmonary disease in 90% of cases.⁷ NTM musculoskeletal infection is uncommon,⁷⁻⁹ but NTM tenosynovitis has been repeatedly reported.¹⁰⁻¹² Wrists and hands are the most frequently reported sites of tenosynovitis, and some have described the presence of multiple granulomatous “rice bodies.”¹⁰⁻¹³ As seen in our patient, *M intracellulare* can infect a single digit and cause tenosynovitis-associated dactylitis.

Use of anti-tumor necrosis factor agents, high-dose corticosteroids, leflunomide, cyclophosphamide, azathioprine, cyclosporine, mycophenolate, and chlorambucil have been associated with NTM infection of soft tissue or joints.¹⁴

■ DISCLOSURES

The authors report no relevant financial relationships which, in the context of their contributions, could be perceived as a potential conflict of interest.

REFERENCES

1. **Olivieri I, Scarano E, Padula A, Giasi V, Priolo F.** Dactylitis, a term for different digit diseases. *Scand J Rheumatol* 2006; 35(5):333–340. doi:10.1080/03009740600906677
2. **Olivieri I, Barozzi L, Favaro L, et al.** Dactylitis in patients with seronegative spondylarthropathy. Assessment by ultrasonography and magnetic resonance imaging. *Arthritis Rheum* 1996; 39(9):1524–1528. doi:10.1002/art.1780390912
3. **Zenone T, Boibieux A, Tigaud S, et al.** Non-tuberculous mycobacterial tenosynovitis: a review. *Scand J Infect Dis* 1999; 31(3):221–228. doi:10.1080/00365549950163482
4. **Bakewell CJ, Olivieri I, Aydin SZ, et al.** Ultrasound and magnetic resonance imaging in the evaluation of psoriatic dactylitis: status and perspectives. *J Rheumatol* 2013; 40(12):1951–1957. doi:10.3899/jrheum.130643
5. **Yoon CJ, Chung HW, Hong SH, Kim CJ, Kang HS.** Case report: MR findings of tuberculous dactylitis. *Eur J Radiol* 2001; 39(3):163–167. doi:10.1016/s0720-048x(01)00327-8
6. **Bhaskar, Khonglah T, Bareh J.** Tuberculous dactylitis (spina ventosa) with concomitant ipsilateral axillary scrofuloderma in an immunocompetent child: A rare presentation of skeletal tuberculosis. *Adv Biomed Res* 2013; 2(2):29. doi:10.4103/2277-9175.107993
7. **Park JW, Kim YS, Yoon JO, et al.** Non-tuberculous mycobacterial infection of the musculoskeletal system: pattern of infection and efficacy of combined surgical/antimicrobial treatment. *Bone Joint J* 2014; 96-B(11):1561–1565. doi:10.1302/0301-620X.96B11.33427
8. **Gundavda MK, Patil HG, Agashe VM, Soman R, Rodrigues C, Deshpande RB.** Nontuberculous mycobacterial infection of the musculoskeletal system in immunocompetent hosts. *Indian J Orthop* 2017; 51(2):205–212. doi:10.4103/0019-5413.201718
9. **Napaumpaiporn C, Katchamart W.** Clinical manifestations and outcomes of musculoskeletal nontuberculous mycobacterial infections. *Rheumatol Int* 2019; 39(10):1783–1787. doi:10.1007/s00296-019-04392-8
10. **Piersimoni C, Scarparo C.** Extrapulmonary infections associated with nontuberculous mycobacteria in immunocompetent persons. *Emerg Infect Dis* 2009; 15(9):1351–1358. doi:10.3201/eid1509.081259
11. **Namkoong H, Fukumoto K, Hongo I, Hasegawa N.** Refractory tenosynovitis with ‘rice bodies’ in the hand due to *Mycobacterium intracellulare*. *Infection* 2016; 44(3):393–394. doi:10.1007/s15010-015-0844-0
12. **Kwan M, Tupler R.** Recurrent nontuberculous mycobacterial tenosynovitis. *Ochsner J* 2021; 21(1):86–89. doi:10.31486/toj.19.0010
13. **Kreutz-Rodrigues L, Bakri K.** Tenosynovitis due to mycobacterium avium complex. *N Engl J Med* 2019; 381(25):2461. doi:10.1056/NEJMicm1901520
14. **Brode SK, Jamieson FB, Ng R, et al.** Increased risk of mycobacterial infections associated with anti-rheumatic medications. *Thorax* 2015; 70(7):677–682. doi:10.1136/thoraxjnl-2014-206470

Address: Hiroaki Nishioka, MD, PhD, Department of General Internal Medicine, Kobe City Medical Center General Hospital, 2-1-1 Minami-machi, Minatogima, Chuo-ku, Kobe City, Hyogo 650-0047, Japan; nishiokahiroaki@hotmail.com