

THE CLINICAL PICTURE

Nami Yoshimura, MD

Department of General Medicine,
Shimane Prefectural Central Hospital,
Shimane, Japan

Takashi Watari, MD, MHQS, MCTM, PhD

General Medicine Center, Shimane University Hospital,
Shimane, Japan; Division of Hospital Medicine, VA Ann
Arbor Healthcare System, Ann Arbor, MI

Keisuke Misao, MD

Department of General Medicine,
Shimane Prefectural Central Hospital,
Shimane, Japan

Toshihiro Imada, MD

Department of General Medicine,
Shimane Prefectural Central Hospital,
Shimane, Japan

Junji Mashino, MD

Department of General Medicine,
Shimane Prefectural Central Hospital,
Shimane, Japan

The double-tongue sign

AN 85-YEAR-OLD WOMAN WITH stage 3 chronic kidney disease presented to our hospital with dyspnea and intermittent mild fever. She had a history of significant odynophagia and dysphagia. In the previous 2 days, the submandibular area had become erythematous and swollen.

The patient's vital signs were the following:

- Glasgow coma Scale 14 out of 15 (ie, responsive)
- Blood pressure 107/60 mmHg
- Pulse rate 91 beats per minute
- Body temperature 36.8°C (98.2°F)
- Respiratory rate 20 breaths per minute
- Oxygen saturation 95% on room air.

Physical examination revealed the “double tongue” sign on the floor of the mouth (**Figure 1**), with tender, slightly erythematous swelling under the jaw. She had slight difficulty opening her mouth, but she had no dental caries or cervical lymphadenopathy.

Laboratory testing on hospital admission revealed the following:

- White blood cell count $6.9 \times 10^9/L$ (reference range 4–11)
- Neutrophils $5.7 \times 10^9/L$ (1.5–8.0)
- C-reactive protein 10.8 mg/dL (0–0.3)
- Blood urea nitrogen 33.5 mg/dL (8–21)
- Creatinine 1.8 mg/dL (0.58–0.96)
- Estimated glomerular filtration rate 20.9 mL/min/1.73 m² (≥ 60).

Laboratory data showed elevated C-reactive protein induced by oral infection, elevated blood urea nitrogen and creatinine levels due to dehydration, and pre-renal acute kidney injury caused by poor oral intake for approximately 2 days.

Computed tomography showed enlarged mylohyoid and geniohyoid muscles, surrounding inflammatory findings, and small gas retentions. There were no findings suggestive of malignant neoplasms

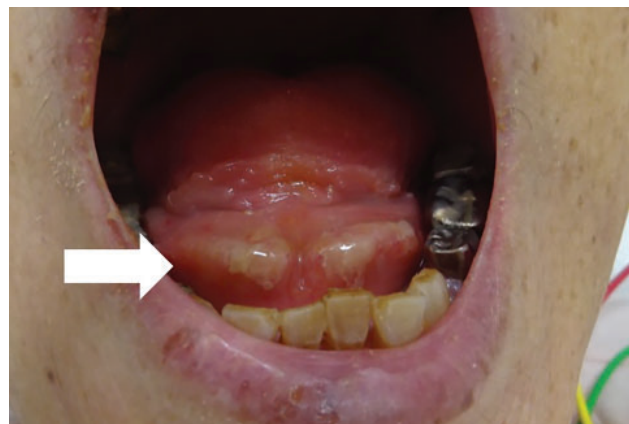


Figure 1. Swelling in the submandibular space pushes the tongue upward, resulting in what resembles a double tongue (arrow).

of the neck, chest, or abdomen. The patient was diagnosed with Ludwig angina based on the physical examination and features noted on computed tomography.

■ TREATMENT FOLLOWED BY A SECOND SIGN

An oral surgeon performed incision and drainage, and the patient was prescribed antibiotic therapy with intravenous ampicillin-sulbactam 1.5 g every 12 hours for 14 days in the hospital. Pus culture detected *Streptococcus parasanguinis* and *Bacteroides fragilis*.

Her recovery was uneventful, and the double-tongue sign disappeared completely at discharge on day 16 without any complications. However, 3 days later, she returned because her tongue had turned black without other symptoms. She was diagnosed with black hairy tongue caused by antibiotic therapy (**Figure 2**). Her tongue color returned to normal spontaneously after 14 days.

doi:10.3949/ccjm.89a.21080

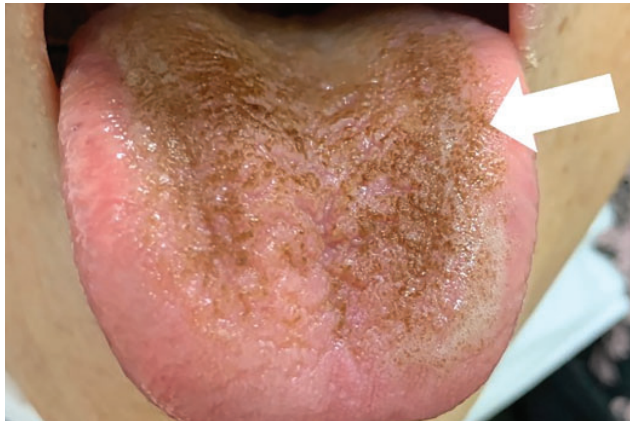


Figure 2. Black hairy tongue sign. Although there are no subjective symptoms, the tongue's surface takes on a dark, hairy appearance (arrow) due to abnormal elongation and discoloration of the filiform papillae. The discoloration cannot be removed by brushing or scraping.

■ TONGUE EXAMINATION KEY TO DIAGNOSIS

This case exemplifies how careful physical examination of the tongue can help achieve a meaningful diagnosis. Ludwig angina is a rare deep-neck infection occurring on the floor of the mouth under the tongue. Prompt treatment is needed to prevent airway obstruction.^{1,2}

In this patient, early recognition of the double-tongue sign resulted in an accurate diagnosis. Although the sensitivity, specificity, and likelihood

■ REFERENCES

1. Watari T, Tokuda Y. Double tongue signs in a case of submandibular space infection. *BMJ Case Rep* 2018; 2018:bcr2018225559. doi:10.1136/bcr-2018-225559
2. Albacete Neto A, Coltro PS, Horácio GS, Almeida IR, Farina Junior JA. Unilateral pectoralis major muscle flap for the treatment of sternal wounds due to Ludwig's angina. *Int Wound J* 2018; 15(1):174–177. doi:10.1111/ivwj.12844
3. Mohamad I, Narayanan MS. "Double tongue" appearance in Ludwig's angina. *N Engl J Med* 2019; 381(2):163. doi:10.1056/NEJMicm1814117

ratios for Ludwig angina were not quantified, the double-tongue sign is a valuable physical finding, characterized by elevated floor of the oropharynx caused by infection in the submandibular space.^{1,3}

Black hairy tongue

Black hairy tongue is characterized by abnormal elongation and discoloration of the filiform papillae, typically resulting in a carpet-like appearance on the dorsal surface of the tongue.^{4–6} Black hairy tongue is a benign and painless condition.^{4–6} However, its etiology and pathophysiology remain vague. Studies suggest that it occurs more commonly in men and is caused by changes in the oral flora due to aging, smoking, alcohol use, poor oral hygiene, and specific antibiotic treatments.^{5,6} An association with beta-lactam antibiotics has been reported.⁶ The condition resolves spontaneously when oral hygiene is maintained.

Tongue examination may not be commonly performed often in clinical practice. However, this case shows that understanding characteristic tongue findings helps achieve a meaningful diagnosis and prevent excessive examination and intervention. ■

Acknowledgments: The authors would like to thank the staff of the General Medicine Center for their passion for community care and attentive patient care. We would also like to thank the general practitioners in Shimane for their guidance in training young practitioners.

■ DISCLOSURES

The authors report no relevant financial relationships which, in the context of their contributions, could be perceived as a potential conflict of interest.

4. Sakaguchi K, Watari T. Tetracycline-induced black hairy tongue. *J Gen Fam Med* 2020; 21(3):80–81. doi:10.1002/jgf2.300
5. Gurvits GE, Tan A. Black hairy tongue syndrome. *World J Gastroenterol* 2014; 20(31):10845–10850. doi:10.3748/wjg.v20.i31.10845
6. Ren J, Zheng Y, Du H, et al. Antibiotic-induced black hairy tongue: two case reports and a review of the literature. *J Int Med Res* 2020; 48(10):300060520961279. doi:10.1177/0300060520961279

Address: Takashi Watari, MD, MQHS, MCTM, PhD, General Medicine Center, Shimane University Hospital, 89-1, Enya-cho, Izumo shi, Shimane 693-8501 Japan; wataritari@gmail.com