

POOR POSTURE AND LOW BACK PAIN

W. J. ZEITER, M.D. and G. J. WARD, M.D.

Clinicians frequently see patients who are obviously in poor health, but in whom no organic disease can be demonstrated. In a large number of these chronically ill patients, poor body mechanics may be playing an important role in the chronic disability, and beneficial effects may be obtained when the error in mechanics is improved or entirely corrected.

The White House Conference on Child Health¹ defines body mechanics as follows: "Body mechanics is the mechanical correlation of the various systems of the body with special reference to the skeletal, muscular, and visceral systems and their neurological associations."

In the following discussion the effects of poor body mechanics shall not be described in detail, but rather the emphasis shall be upon the essential changes that are produced and upon the methods for correcting faulty posture.

Every clinician has noted that the individual who stands with erect posture feels alert, looks alert, and portrays energy and a sense of well-being; whereas, the slumped individual with a marked forward curve of the cervical spine or increased lordosis makes the opposite impression. In our armed services where much attention is given to the posture of the fighting man, the value of good posture is recognized. If the civilian population were more posture conscious, they too would be benefited.

Because of the differences in body builds, each patient's problem must be individualized. Accordingly, no scale can be set up which will be adaptable to every patient. As Goldthwait² has so aptly stated, when a mechanical engineer studies a machine he first looks at it to see how it is made, and then examines it to see how near to 100 per cent it is in alignment and function. The less well the machine is aligned, the greater is the strain and the potential of trouble. Likewise in the human machine malalignment or faulty mechanics are potentials of trouble and should be recognized by the physician as such. In order that the various complicated systems may function with the least amount of wear and the greatest amount of power, the body should be developed to its highest mechanical efficiency.

The bones, ligaments, and muscles determine the range of motion of a particular joint. Faulty body mechanics may produce a long series of anatomical malalignments which if allowed to progress can result in severe visceral, somatic, and neurological symptoms. In the bony

structure of the vertebral column there are certain curves, and all the vertebrae have a certain range of motion. If these curves are accentuated, strain is placed upon the articulating facets, ligaments, and musculature. With marked accentuation pressure may be produced on the peripheral nerves as they leave the spinal column. The site of pain depends upon whether the maximum malalignment is in the upper or lower spine. Occipital headaches or pain in the neck not infrequently result from faulty mechanics of the cervical spine.

The greatest flexibility of the spine is in the region of the dorsolumbar segments, and because of this greater flexibility mechanical error often occurs at this site. Probably the most common clinical problem from chronic postural strain is low back pain. The exercises which shall be described later in this discussion are directed primarily toward the correction of mechanical strain producing low back pain in which organic disease has been ruled out.

Pressure on the nerves in the dorsolumbar region may produce referred pain in the region of the gallbladder, appendix, or lower abdomen. After organic disease has been ruled out, attention should be directed to postural defects as a possible etiological factor.

Because of the attachment of the ribs to the dorsal vertebrae, an increased dorsal curve will produce a downward inclination of the ribs, thereby flattening the chest to more closely approximate the ribs and to greatly decrease the depth of the chest, which in good body mechanics is about two-thirds of its width. This condition is more likely to occur in the slender type of individual. With the flattening of the chest the abdominal muscles become relaxed and less efficient in supporting the abdominal viscera. As the circumference of the bony thorax is diminished, the origins and insertions of the diaphragm are more closely approximated with a resultant diminution in efficiency. The reserve function for unusual exertion such as is needed in singing is also decreased since the diaphragmatic excursion in the standing position is at, or very near, the point of full inspiration. Because the great abdominal veins are attached to, and pass through the diaphragm, the diaphragm has an additional function of aiding the return of the blood to the right heart. Accordingly, the importance of good posture and breathing exercises should be emphasized in disease in which maximum circulatory and respiratory efficiency is desired.

When the position of the diaphragm is low and the abdominal muscles relaxed, the abdominal cavity alters its shape from the ideal. In the ideal position the abdominal cavity is largest in the upper portion and decreases in size in the lower portion, assuming a pear shape with the top of the pear pointing downward. If this position is assumed,

the abdominal muscles evidence good tonus and help to keep the abdominal viscera elevated. If the abdominal muscles are relaxed, the opposite occurs.

Before measures for the correction of faulty body mechanics can be applied, the various gradations in body carriage must be understood. The Children's Bureau of the U. S. Department of Labor³ directs attention to these variations and describes three types of anatomic structure.

1. "The thin type has a torso long and slender or delicate and narrow and a long, thin neck. The length in the lumbar region is striking. Frequently there may even be six lumbar vertebrae instead of the usual five. The elongated spine gives more flexibility, and this explains the marked slump, or ptosis, possible in these persons. They sometimes look as if some heavy force were pushing them down from above; so much so that they sway far backward in the upper back and protrude far forward in the lower back, the pelvis tipping forward in the lower spine. The shoulders may become markedly rounded and forward and the shoulder blades scaphoid. The extremities and their muscles are usually long and slender.

2. "The broad type includes the heavy-looking, 'broad-backed' persons with large skeletons. The neck is short and 'chunky.' The torso is broad and relatively short. The lumbar region is short, sometimes because there are only four lumbar vertebrae instead of the usual five and sometimes because the sacrum is set well down between the hip bones. Because of the very construction of the spine the lumbar curve is less marked. Flexibility is lacking in this sturdily built spine. The extremities are large and broad. This is the type that tends to be obese.

3. "In the intermediate type the torso is a compromise in length and breadth between the other two types. The normal rounded curves of the spine, if they become exaggerated, appear mild and gradual. The sharp 'corners' of this thin type and the large fatty deposits of the broad type are missing. The neck may be almost as long as that of the thin type; or it may be short, though hardly so thick and 'chunky' as in the broad type. The musculature is firm. Flexibility of the spine, though not so marked as in the thin type, is much greater than in the broad type. This intermediate class is heterogeneous; it should include all individuals that do not fall readily into either of the other groups."

Various methods have been suggested for the correction of faulty body mechanics, and the following exercises describe the method we use to correct mechanical strain, especially involving the low back.

The exercises are taught in two positions: (1) in the recumbent position, and (2) in the erect position. In the preceding paragraphs

emphasis has been placed upon the importance of chest expansion and satisfactory range of motion of the diaphragm. It is well therefore to begin with the breathing exercises which can best be done on a firm treatment table which is perfectly flat.

Exercise 1. The patient lies flat on the back without a pillow under the head. The knees are flexed with the feet flat on the table. The fingers are inserted into the costal margin to assist in raising the costal margins in deep inspiration. Inhalations are taken through the nose and exhalations through the mouth, and an attempt is made to expand the thoracic cage to its maximum limits.

Exercise 2. After the above exercise, diaphragmatic breathing is developed. This is accomplished by attaining complete expansion of the chest. Respiration is continued by diaphragmatic movement while the chest is held expanded.

Exercise 3. Pelvis tilting. The knees are flexed with the feet flat upon the table to help eliminate the lumbar curve so that it approximates the table. The knees are kept in the flexed position, and the pelvis is rolled forward to produce a lordosis and then rolled backward to eliminate the lumbar curve. The motion primarily involves the gluteal and abdominal muscles which are of prime importance in maintaining the proper pelvic angle.

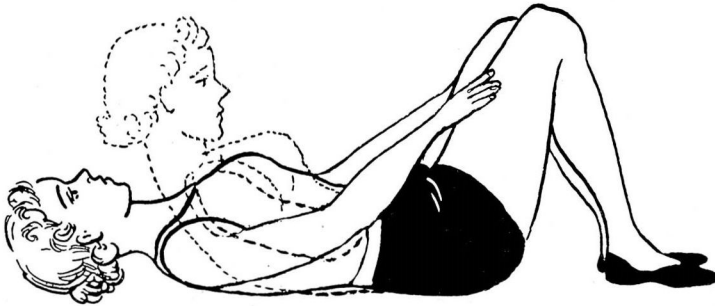

Fig. 1

Exercise 4. Head raising. (Fig. 1) With severe lordosis head raising is sometimes necessary to assist in the correction. The knees are kept in the flexed position, and the arms are extended so that they cannot be used for support. Then the head is raised from the table.

Exercise 5. Pelvis tilting with gradual extension of the legs. The pelvis is tilted with the knees flexed and the feet flat on the table to eliminate the lumbar curve as in Exercise 3. The heel of the right foot is kept in contact with the table, and the leg is gradually extended until flat on the table. The same procedure is then carried out with the left leg. During this exercise every attempt is made to keep the lumbar spine flat.

Exercise 6. The supine position is assumed with pelvis tilted to flatten back as in Exercise 3. The right leg is gradually extended until it is flat on the table. The leg is then flexed upon the trunk to the maximum degree while the knee is kept straight and all motion of the limb occurs at the hip. The leg is then brought back to the table. The same procedure is repeated with the left leg.

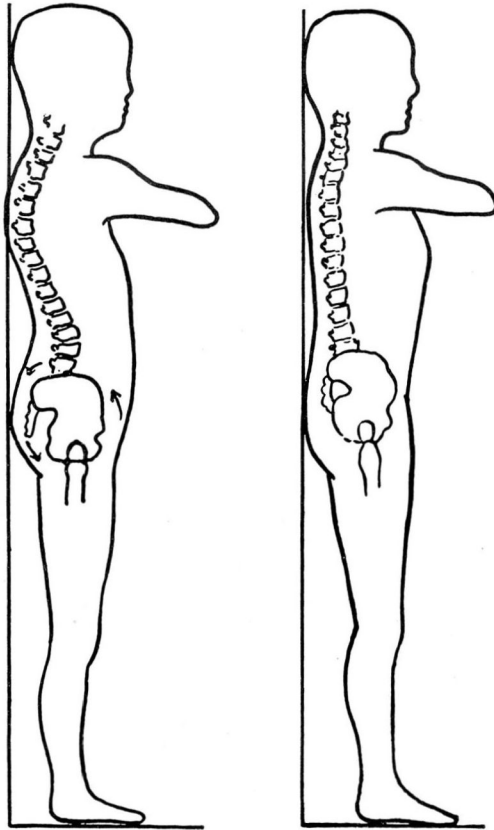


Fig. 2

Exercise 7. (Fig. 2) Pelvis tilting and flattening the back against the wall. The patient stands with the heels 4-6 inches from the wall. The buttocks, shoulders, and head touch the wall, and the chin is held at a right angle. The patient then elevates the symphysis upward, which rotates the pelvis backward thus reducing the lumbar curve, and tries to press the lumbar spines against the wall.

Exercise 8. After the position has been assumed properly as directed in Exercise 7, the patient is instructed to walk forward two or three paces, rise on the toes several times, and return to the wall. During this maneuver the patient is attempting to maintain the position achieved by Exercise 7. The return to the wall acts as a check upon the degree of correct posture maintained during the simple process of walking.

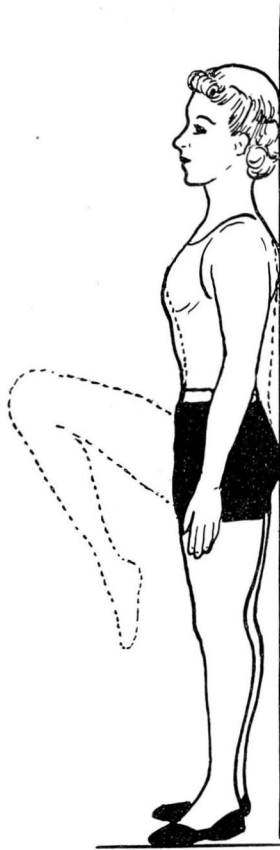


Fig. 3 .

Exercise 9. The patient assumes the position as in Exercise 7. The right knee is flexed upon the abdomen, as in Fig. 3, and this position is exaggerated by grasping the knee with both hands and pulling it toward the abdomen while the lumbar spine is simultaneously pressed against the wall. The leg is gradually lowered to the standing position, and the position of the lumbar spine is maintained as achieved with the leg flexed. The same procedure is carried out with the left leg.

LOW BACK PAIN

Exercise 10. This exercise consists merely in walking about for a few minutes and maintaining a flattened lumbar curve. This maneuver is primarily to acclimate the patient to the new and as yet unfamiliar position.

Exercise 11. The patient stands against the wall and again assumes the correct posture as in Exercise 7. He then flexes the spine and allows the arms to drop forward loosely, and then straightens up having each vertebra touch the wall beginning in the sacrum and progressing up the spine.

The patient executes each exercise about ten times unless there is marked weakness or fatigue which would limit the number of times the procedure is repeated.

The described exercises are directed toward correcting mechanical error especially of the dorsolumbar region. In some instances more elaborate and detailed exercises are needed to correct malposition. The correction of faulty body mechanics requires more than a few minutes a day spent in performing exercises. These exercises will give tonus to those muscles instrumental in maintaining good posture. However, the patient must become posture conscious and make a wilful effort throughout the day to assume the posture reached in his exercises, and attempt to fulfil the ten commandments of good posture as suggested by Lewin.⁴

1. Stand tall.
2. Sit tall.
3. Walk tall and "chesty" with weight transmitted to balls of feet.
4. Draw in abdomen, pulling it backward and upward.
5. Keep shoulders high and square.
6. Pull chin down toward collar button.
7. Flatten hollow of back by rolling pelvis downward and backward.
8. Separate shoulders from hips as far as possible.
9. Lie tall and flat.
10. Think tall.

REFERENCES

1. White House Conference, Body Mechanics. New York: The Century Co., 1932.
2. Goldthwait, J. E., Brown, L. T., Swaim, L. T., and Kuhns, J. G.: Body Mechanics in Study and Treatment of Disease. Philadelphia: The J. B. Lippincott Co., 1934.
3. Klein, Armin: Posture Clinics, Children's Bureau, U. S. Dept. of Labor, Washington, D. C.
4. Lewin, P.: Posture. *Hygeia*, 13:221-236 (March, 1935).