

# HEMIPLEGIA AND CEREBROVASCULAR DISEASE

LOUIS J. KARNOSH, M. D.

Hemiplegia in the aging patient is usually regarded as a stereotyped clinical event and the lesion producing it an equally stereotyped pathological disturbance. Much of this casual attitude toward this condition is probably due to the influence of Charcot's forceful and convincing manner of designating the so-called lenticulostriate branch of the middle cerebral circulation as "the artery of apoplexy".

More extended and detailed studies by clinicians and pathologists have demonstrated no Greek simplicity in the problem of apoplexy. There are variations here as there are in other morbid processes in other organs.

## BLOOD SUPPLY OF INTERNAL CAPSULE

The blood supply of the internal capsule and of the adjacent basal ganglia, which are almost invariably involved in the vascular lesion of hemiplegia, is by no means a settled matter. As pointed out by Alexander,<sup>1</sup> textbooks of anatomy are rather vague and perfunctory in describing this phase of cerebral circulation, and many still refer to a definite lenticulostriate artery as if it were a constant and clearly demonstrable structure.

Dismissing the concept of a single large "artery of apoplexy", Alexander<sup>1</sup> demonstrated by an ingenious injection technic that the vulnerable internal capsule and the adjoining gray masses are supplied by a series of small arteries or arterioles which arise directly from the large vessels as these emerge from the circle of Willis. These small arteries are arranged in tiers or clusters and at right angles from the parent artery, and most of them penetrate the brain substance in the anterior perforated space. In every respect, they resemble the arterioles penetrating from the circle of Willis into the hypothalamus and those branching from the basilar artery which enter the pons. Like the latter, they are readily subject to thromboses and to miliary aneurysms.

Most of these striate arterioles arise from the proximal portion of the middle cerebral artery. The most crucial part of the internal capsule, that is, the knee, may have a small branch directly from the internal carotid artery itself. (See Fig. 1.) Finally, there is the longest and most clearly defined vessel known as the anterior choroidal artery which also arises from the internal carotid and supplies the most caudal portion of the internal capsule and other significant structures, which give its syndrome a special distinction as pointed out by Abbie.<sup>2</sup>

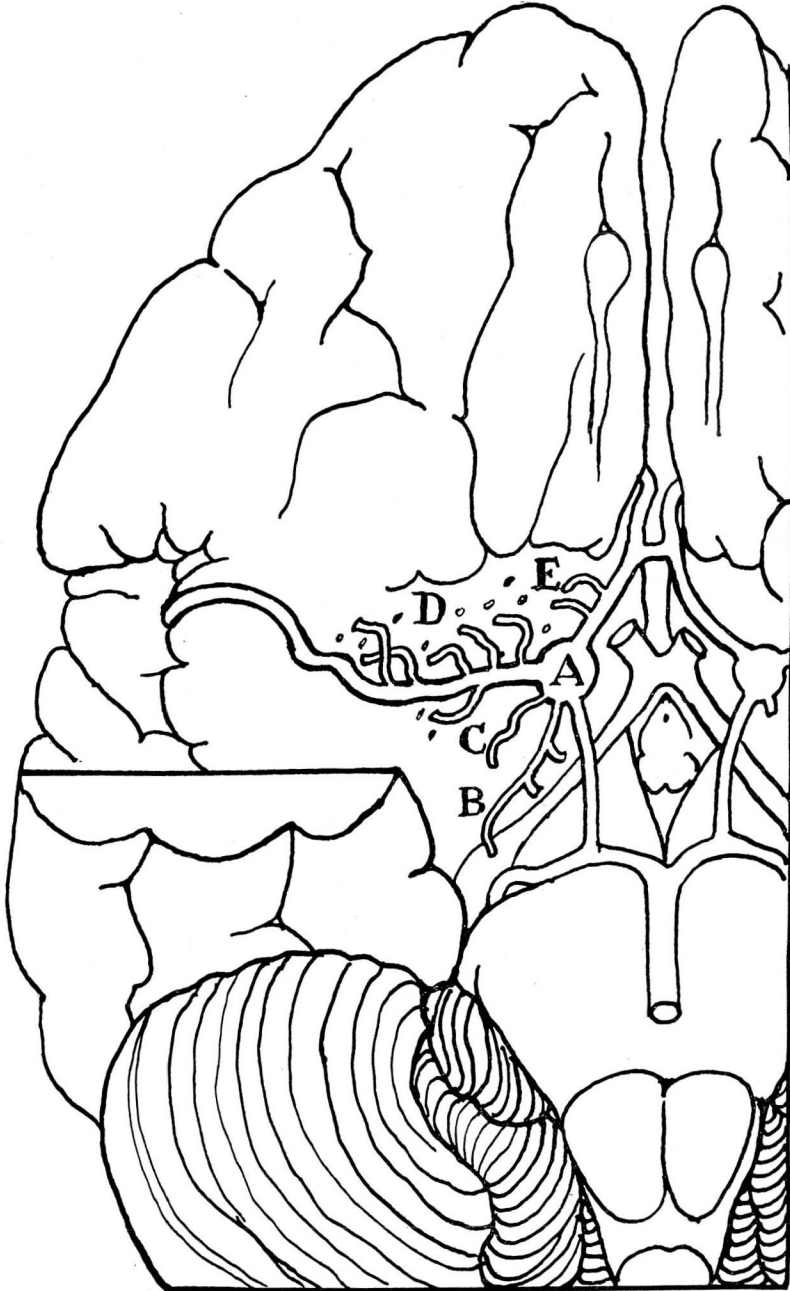

FIGURE 1. Scheme showing the position of the arterioles which supply the basal ganglia and the internal capsule (after Alexander).  
A—internal carotid artery, B—anterior choroidal artery, C—capsular artery arising directly from the internal carotid, D—striate arterioles from the middle cerebral artery, E—striate arterioles from the anterior cerebral artery. All the striate arterioles enter the brain through the anterior perforated substance.

## SURVEY OF MATERIAL

A survey of the clinical records and the necropsy reports of 185 patients who presented some degree of hemiplegia was made by the writer and confirms the well recognized propensity of the middle cerebral circulation to both hemorrhage and softening (Fig. 2).

In 110 cases of cerebral hemorrhage 87 brains, or 80 per cent, presented the lesion in the middle cerebral branches. In 66 brains with thrombosis, 77 per cent revealed the softening in the same circulation. Hence, the fact is clearly presented that the middle cerebral artery with its branches is the structure which is most vulnerable to the most common lesion appearing in the human brain.

In addition to this garden variety of vascular brain disease, wherein the bleeding or softening was found to be in and about the basal ganglia, the material included 5 patients with hemiplegia who presented a primary hemorrhage in the pons and 4 cases with softening in the medulla.

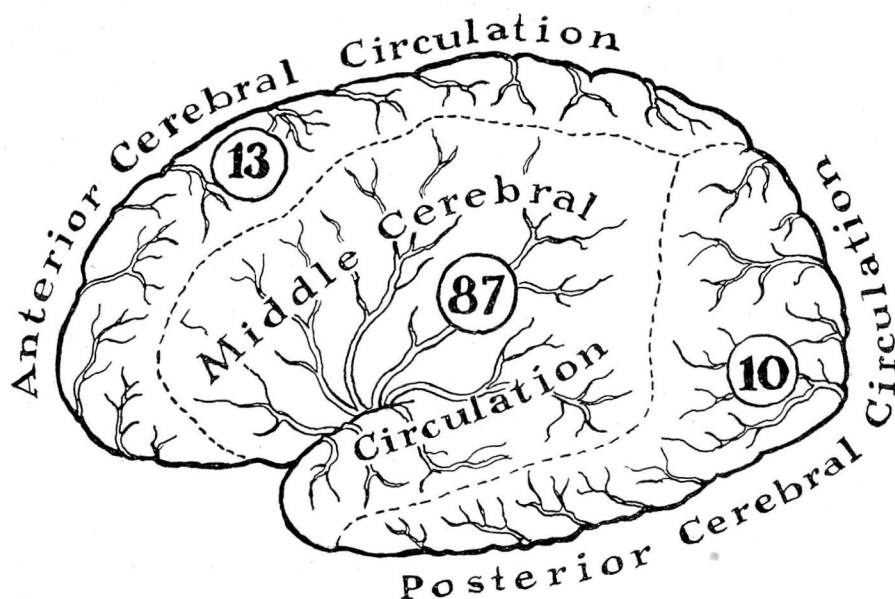
As indicated before, all these patients displayed clinically at one time or another some degree of hemiplegia or weakness of one side of the body. By scrutinizing this symptom as to quality and severity, by inquiring into associated signs such as aphasia, sensory defects such as a concomitant hemianesthesia or hemianopsia, an attempt was made to furnish a rough correlation between the clinical features and the general site of the offending lesion.

Naturally, many of the clinical descriptions of the paralysis in the hospital charts were incomplete, sketchy, and often very confusing. For this reason, only the crudest delineation of hemiplegic types can be offered. Since this study is essentially a clinico-anatomical correlation, no differentiation will be made between thrombosis and hemorrhage.

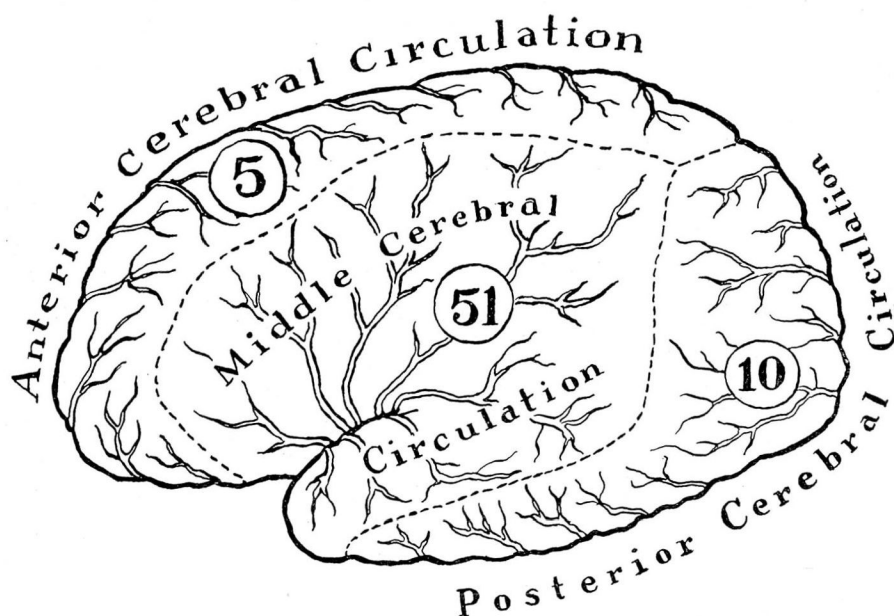
## ANATOMICAL SITE OF APOPLEXY

A quick inspection of the lesion in 102 specimens, which constitute 55 per cent of the entire collection, demonstrated the most typical anatomical site of apoplexy.

Contrary to common impression, this site is not in the internal capsule, but actually involves the external capsule, the upper and outer part of the putamen and that part of the corona radiata which carries the long fibres from the facial and arm area. This is in accord with the findings of Freeman<sup>3</sup> who believes that this vulnerable zone is the site of an embryonic cleavage. According to Alexander,<sup>1</sup> this area is supplied, not



*The relative frequency of **Hemorrhage** in the three main cerebral circulations*



*The relative frequency of **Softening** in the three main cerebral circulations*

FIGURE 2

by a lenticulostriate artery, but by the most distal striatal arterioles which arise directly from the middle cerebral artery.

If this be the typical vascular insult to the brain, the question arises as to what form of hemiplegia is its typical counterpart. A composite of all the data on the charts would indicate that such a lesion produces the simplest form of hemiplegia. The infirmity is essentially a spastic paralysis involving the face and arm, but rarely the lower extremity. Tendon reflexes are invariably exaggerated and pathological responses such as the Babinski and the Hoffman are the rule. Motor aphasia is common if the paralysis is on the right side. There are rarely associated disturbances such as hemianopsia, although a small number of these patients complained of vague parasthesias on the paralyzed side. Only one chart recorded a sharply defined homolateral anesthesia to touch.

#### DEEPER CEREBRAL LESIONS WITH ATYPICAL HEMIPLEGIAS

In 22 specimens the area of softening or hemorrhage was more extensive and more centrally located, the lesion involving the internal capsule, the globus pallidus, and even the thalamus. In 5 cases the hemorrhage extended into the lateral and third ventricles. This group represents in general the more severe and more short-lived processes, for the clinical story was usually one of rapid onset, severe shock, coma, and short period of survival.

Because of the profound stupor or obtundation, clinical description was found to be exceptionally meager. The hemiplegia in this second group was usually complete, involving face, arm, and leg to a pronounced degree. Tendon reflexes were generally absent or sluggish; the muscle tone was flaccid in 15 cases. Even in those instances where reflex function was restored, the limbs usually remained in flaccid state.

Sensory disturbances were found in 10 of these patients. This usually consisted of an hypoaesthesia to both touch and pin prick on the paralyzed side of the body, the facial area frequently escaping the sensory defect.

That so many of the patients in this group were found to have such a sensory disturbance is a favorable comment on clinical acumen, for it must be emphasized that this symptom is only elicited with difficulty in an elderly or mentally torpid individual.

This frequent coexistence of flaccid hemiplegia and hemianesthesia may not be entirely a fortuitous observation. When hemianesthesia is present, it is implied that the brain lesion involves either the thalamus or the sensory tracts. Verhart<sup>4</sup> made serial sections in 21 cases of hemiplegia and concluded that the flaccid form occurs when both the sensory

and pyramidal systems are destroyed. Aring<sup>5</sup> also claims that flaccid hemiplegia is found in deep cerebral lesions but attributes the cause to destruction of the basal ganglia rather than the thalamus. Davison and Bieber<sup>6</sup> in their studies of cerebral flaccidity in man likewise found hemianesthesia in all their cases of flaccid paralysis, but do not regard this sensory disturbance as a causative factor. None the less, this concept of the production of flaccid hemiplegia appears more plausible to the clinician than that offered by the Yale group<sup>7</sup> of neurophysiologists who consider this phenomenon to be an expression of injury to the purely motor area of the cortex.

Hence, in those hemiplegias showing the deeper and more mesial lesion, the clinical picture may be one of flaccid hemiparalysis with or without a hemianesthesia.

In two of the patients in this group the clinical findings included the complete triad of flaccid hemiplegia, hemianesthesia, and hemianopsia. Here, it is believed, the lesion was specifically one in the anterior choroidal artery, for this interesting blood vessel supplies not only the pyramidal fibres, but also the ascending sensory tracts to the thalamus and the external geniculate body where the optic tract is interrupted. In one case a small ruptured aneurysm was actually revealed in this artery near its junction with the internal carotid.

#### HEMIPLEGIA IN PONTINE HEMORRHAGE

Hemorrhage and thrombosis along the brain stem are not as quickly detected as are such disturbances in the cerebrum itself. This applies particularly to hemorrhage into the pons.

Only in one instance out of the 5 cases of pontine hemorrhage was the diagnosis accurately made; in the remaining 4 the condition was regarded as a cerebral ictus. In the latter group the clinical course was rapid, coma quickly intervened, and focal symptoms were overshadowed by the picture of total collapse.

In these pontine hemorrhages, which are not uncommon and which are frequently terminal lesions in hypertensive brain disease, the paralysis was not a clear-cut hemiplegia, but was more often a general flaccid weakness. The fever reaction was more pronounced in these patients, and respiratory difficulties were prominent. If the patient survives the acute shock phase, which is rarely the case, more focal symptoms may arise such as external squint and difficulty in swallowing, even though throat reflexes may be very active. Occasionally, there may be the peculiar symptom of compulsive laughing or crying—the syndrome of pseudobulbar palsy.



## HEMIPLEGIA IN LESIONS OF THE MEDULLA

Hemiplegia or hemiparesis was a clinical notation in 3 of the 4 patients who were found to have a thrombosis in the lateral portion of the medulla. Strictly speaking, these individuals did not have a hemiplegia, but a hemihypotonia and a hemiataxia, although they may have complained of a unilateral subjective weakness. In this condition, which is usually due to a thrombosis of the posterior inferior cerebellar artery, the motor symptoms are indeed unilateral. The patient falls to the affected side as if he were hemiplegic, but the voluntary control of the limbs is intact. Moreover, there is usually a rotatory nystagmus, and on the weakened side there is usually a loss of pin-prick or pain sense over the trigeminal distribution of the same side. The corneal reflex therefore is frequently absent.

In the remaining 52 cases the clinical data were so scanty that no conclusions can be offered. In many of these the lesions were far too extensive to determine what vessels or groups of vessels were the actual offenders in the production of the hemorrhage or thrombosis.

## SUMMARY

Only a general correlation can be made between the brain lesion of apoplexy and the type of hemiplegia which may be produced.

The middle cerebral artery with its branches, particularly its striate arterioles, furnishes the most frequent site for hemorrhage and thrombosis.

The most distal of these branches, when damaged, produces the simplest and most common form of hemiplegia, usually of the spastic type.

Deeper and more proximal branches of the middle cerebral artery are the sites of lesions which cause a more complete and more flaccid form of hemiplegia which is often associated with a homolateral hemianesthesia.

A thrombosis or hemorrhage of the anterior choroidal artery is indicated when the hemiplegia is flaccid, and there is not only an associated hemianesthesia, but also an hemianopsia.

Pontine hemorrhage produces a weakness rather than a definite hemiplegia and is usually a prelethal manifestation in malignant hypertension.

In medullary vascular disease the most common ictus is a thrombosis of the posterior inferior cerebellar artery. The unilateral weakness is

rarely a true hemiplegia, but is usually a hemihypotonia with ataxia, anesthesia of the same side of the face, and a rotatory nystagmus.

#### BIBLIOGRAPHY

1. Alexander, Leo.: The Vascular Supply of the Striopallidum. The Diseases of the Basal Ganglia, Research Publications, Association for Research in Nervous and Mental Diseases (Baltimore: Williams and Wilkins Co., 1942), Vol. 21, p. 77.
2. Abbie, A. A.: The clinical significance of the anterior choroidal artery. *Brain*, 56:233-246, 1933.
3. Freeman, Walter: Neuropathology, The Anatomical Foundation of Nervous Diseases (Philadelphia and London: W. B. Saunders Company, 1933), Cerebral hemorrhage, p. 108.
4. Verhart, W. J. C.: Flaccid hemiplegia of cerebral origin. *Psychiat. en neurol. bl.* 41:211-217, 1937.
5. Aring, Charles D.: Flaccid hemiplegia in man. *Arch. Neurol. & Psychiat.* 43:302-317 (February) 1940.
6. Davison, C., and Bieber, I.: The premotor area: Its relation to spasticity and flaccidity in man. *Arch. Neurol. & Psychiat.* 32:963-972 (November) 1934.
7. Fulton, J. F.: Physiology of the Nervous System (New York: Oxford University Press, 1938), p. 675; footnote 1.