

TABLE OF CONTENTS

FROM THE EDITOR 587

A useful gap 587

A very low anion gap can suggest a laboratory measurement error or provide a clue to clinically important protein abnormalities or ingestions that warrant specific investigation.

Brian F. Mandell, MD, PhD

THE CLINICAL PICTURE..... 599

vOka vaccine-associated disseminated varicella zoster 599

The patient had received the live attenuated vaccine 1 month before presentation. He had no history of varicella infection.

Peter R. Hyson, MD; Louis B. Polish, MD

THE CLINICAL PICTURE..... 601

Masked tinea 601

A result of daily mask-wearing during a long hospitalization.

Ayano Hamai, MD; Yukinori Harada, MD, PhD

1-MINUTE CONSULT 603

Should midodrine be used as an intravenous vasopressor-sparing agent in septic shock? 603

Research and robust data are still lacking regarding use of midodrine in this setting.

Simran Gupta, MD; Ayan Sen, MD; Aman Verma, DO

1-MINUTE CONSULT 607

Should I start an SGLT-2 inhibitor in my patient with heart failure and chronic kidney disease? 607

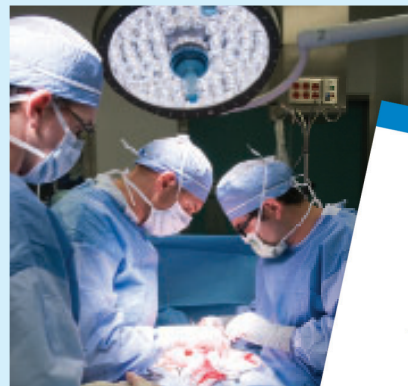These conditions often co-exist and can have complex interactions. The progression of kidney disease increases the risk of major adverse cardiovascular events.

Richard Sekerak, MD; Johanna Ben-Ami Lerner, MD; Pooja Prasad, MD; Megha Prasad, MD

CONTINUED ON PAGE 585

Upcoming Features

- Understanding *MTHFR* mutations and thrombosis risk
- Cirrhosis: Primary care approaches to screening, immunization, and lifestyle modifications



CONTINUED FROM PAGE 581

1-MINUTE CONSULT**Should you use compression duplex ultrasonography to detect deep vein thrombosis to evaluate unexplained fevers?** **611**

The authors provide recommendations on when to order imaging of the extremities in the evaluation of hospitalized patients with unexplained fever.

Daniel Rozenbaum, MD; Anirudh Yalamanchali, MD, MS; Deborah Hornacek, MD, FSVM

GUIDELINES TO PRACTICE**Inpatient glycemic management in noncritically ill patients: Updated guidelines** **615**

The guidelines include a role for newer diabetes technologies and nontraditional insulin and noninsulin therapies.

Michelle D. Lundholm, MD; Oscar L. Morey-Vargas, MD

REVIEW **CME MOC****Evaluating a low anion gap: A practical approach** **619**

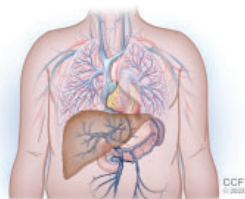
In teaching and in practice, little attention is given to a low anion gap, an oversight that can result in a missed opportunity to diagnose acute or chronic disorders requiring treatment.

Lawrence A. Haber, MD; Gurpreet Dhaliwal, MD; Lowell Lo, MD; Gabrielle Rizzuto, MD, PhD

1-MINUTE CONSULT**What is the most appropriate management of patients with acute decompensated heart failure who develop in-hospital hypotension?** **625**

The authors offer a tailored approach to risk-stratification in these patients that focuses on early recognition and management of symptomatic and clinically significant hypotension.

Lorenzo Braghieri, MD; Warren A. Skoza, MD; Osamah Z. Badwan, MD; Paulino Alvarez, MD

REVIEW**Portopulmonary hypertension: A focused review for the internist** **632**

Key aspects of screening, diagnosis, and treatment, and a review of the various pulmonary hemodynamic patterns encountered in patients with liver disease.

Mamta S. Chhabria, MD; Leela Krishna Teja Boppana, MD; Gaurav Manek, MD; Adriano R. Tonelli, MD, MSc

LETTERS TO THE EDITOR**A new paradigm for adult ADHD** **592**

Vania Modesto-Lowe, MD, MPH; Samantha Frigon

A new paradigm for adult ADHD **592**

Uche Nkanginieme, Medical student

In Reply: A new paradigm for adult ADHD **593**

Michael J. Manos, PhD; Elizabeth J. Short, PhD

DEPARTMENTS**CME Calendar** **590****CME/MOC Instructions** **640**