

TABLE OF CONTENTS

FROM THE EDITOR 270

Aspirin in primary prevention of cardiovascular events: Key questions remain 270

Are we done with the issue of aspirin in primary prevention? Not quite yet.
 Brian F. Mandell, MD, PhD

THE CLINICAL PICTURE..... 277

Chondrodermatitis nodularis helioides 277

The patient first noted the mildly tender, nonpruritic lesion on his left ear after he began sleeping on a firmer pillow.
 Maggie So, MD, FACP; Randall S. Edson, MD, MACP, FIDSA

THE CLINICAL PICTURE..... 279

Cholesteatoma 279

The patient’s audiogram showed left-sided conductive hearing loss, and examination revealed an atelectatic tympanic membrane on the left with a retraction pocket and keratin debris.
 Malek H. Bouzahr, MD; Suat Kilic, MD; Samantha Anne, MD

1-MINUTE CONSULT 283

Should my elderly hospitalized patient with acute onset of altered mental status undergo stat head CT? 283

Clinical acumen and use of delirium scoring tools help narrow the range of possible causes for the individual patient and guide decisions on the need for further testing and imaging.
 Gilad Muth, DO; Thomas A. Bayer, MD; Richard Libman, MD

GUIDELINES TO PRACTICE 287

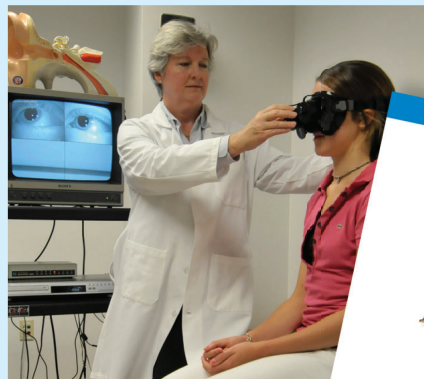Aspirin for primary prevention of cardiovascular disease: What do the current USPSTF guidelines say? 287

A concise overview of the US Preventive Services Task Force recommendations.
 Sanjoyita Mallick, DO; Gautam R. Shroff, MBBS; Mark Linzer, MD

CONTINUED ON PAGE 269

Upcoming Features

- **Celiac disease: Who to test and how**
- **Urine antigen testing for *Legionella pneumophila*: When is it needed?**



CLEVELAND
 CLINIC
 JOURNAL OF
 MEDICINE

CONTINUED FROM PAGE 265

1-MINUTE CONSULT

What is the optimal approach to infiltration and extravasation of nonchemotherapy medications? 292

The immediate response is warm or cold compression and assessment of the severity.

Abby Tarpey, PharmD; Shraddha Narechania, MD, FCCP; Mark Malesker, PharmD, FCCP, FCCM, FASHP, BCPS

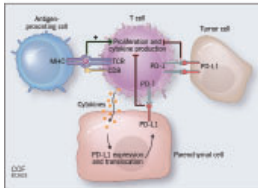
COMMENTARY

The perfect storm: An unseasonably early RSV annual epidemic, a severe annual flu epidemic, and a smoldering COVID-19 pandemic 297

The author presents scenarios illustrating the overlapping clinical manifestations of respiratory viral infections that challenge clinical diagnosis.

Sherif Beniameen Mossad, MD, FACP, FIDSA, FAST

REVIEW **CME | MOC**



Endocrinopathies from checkpoint inhibitors: Incidence, outcomes, and management 307

A review of the incidence and severity of each immune checkpoint inhibitor-related endocrinopathy, factors related to toxicity risk, and principles of management.

Randol Kennedy, MD, FACP; Hussein Awada, MD; Naga Vura, MD; Daniela Ciltea, MD; Michael Morocco, MD

EDITORIAL

Reincarnating autoimmunity: Immune-related adverse events as new diseases 318

The range of adverse events is broad. Any organ can be affected, and any naturally occurring autoimmune process can be mimicked by the massive inflammation generated by checkpoint inhibition.

Pauline Funchain, MD

LETTERS TO THE EDITOR

Resistant hypertension: A stepwise approach 273

Yehia Yousri Mishriki, MD

Resistant hypertension: A stepwise approach 274

Leslie E. F. Page, DO, MPH

DEPARTMENTS

CME Calendar 263

CME/MOC Instructions 320