

## THE CLINICAL PICTURE

### Li-wen Zhang, MD

Department of Dermatovenereology,  
Chengdu Second People's Hospital,  
Chengdu, Sichuan, China

### Wen-ju Wang, MD

Department of Dermatovenereology,  
Chengdu Second People's Hospital,  
Chengdu, Sichuan, China

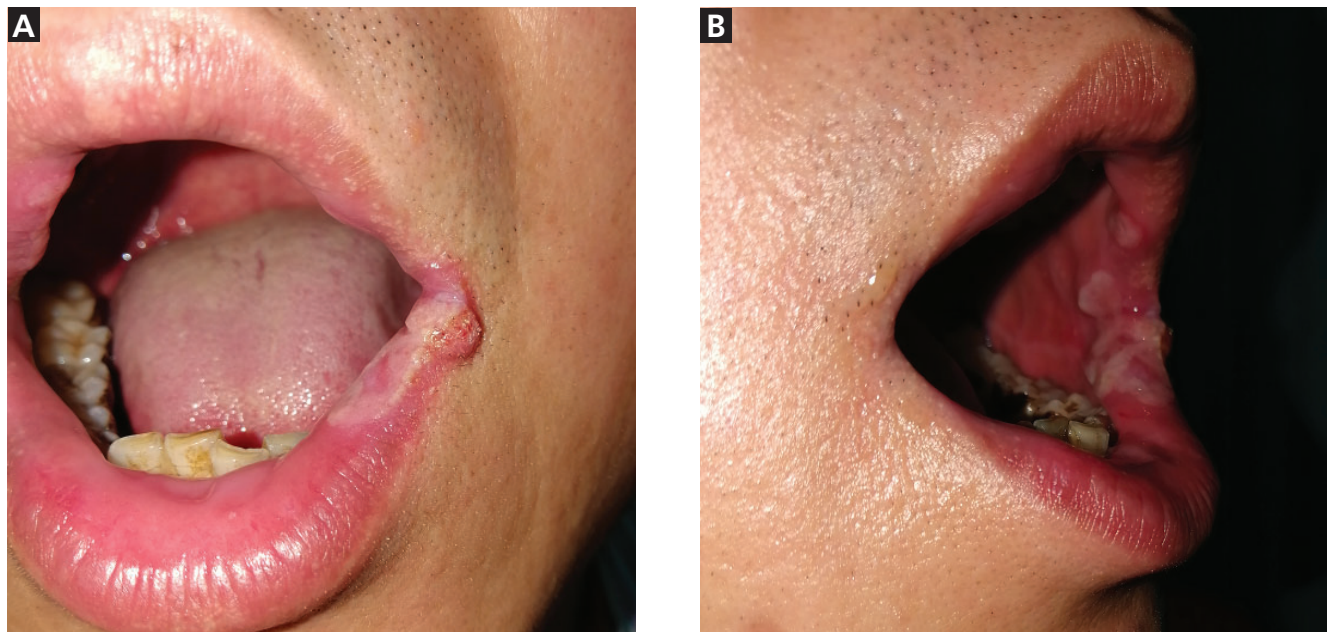
### Tao Chen, MD, PhD

Department of Dermatovenereology,  
Chengdu Second People's Hospital,  
Chengdu, Sichuan, China

### Rong-hua Xu, MD

Institute of Dermatology,  
Chengdu Second People's Hospital,  
Chengdu, Sichuan, China

# Asymptomatic oral plaques and erosion



**Figure 1.** (A) An indurated and painless nodule and plaque on the lower lip. (B) Multiple off-white plaques and erosion on the left buccal mucosa.

**A** 47-YEAR-OLD MALE PRESENTED with a 4-week history of asymptomatic plaques and erosion on the left buccal mucosa and lower lip (Figure 1). He reported seeing a stomatologist, but the prescribed treatment was ineffective. He was then referred to the dermatology department because similar lesions later appeared in genital and perineal regions (Figure 2). He had several high-risk sexual behaviors in the past year.

*Treponema pallidum* particle agglutination testing was positive, and the toluidine red unheated serum test titer was high at 1:32. These results along with the presence of oral and genital-perineal condyloma

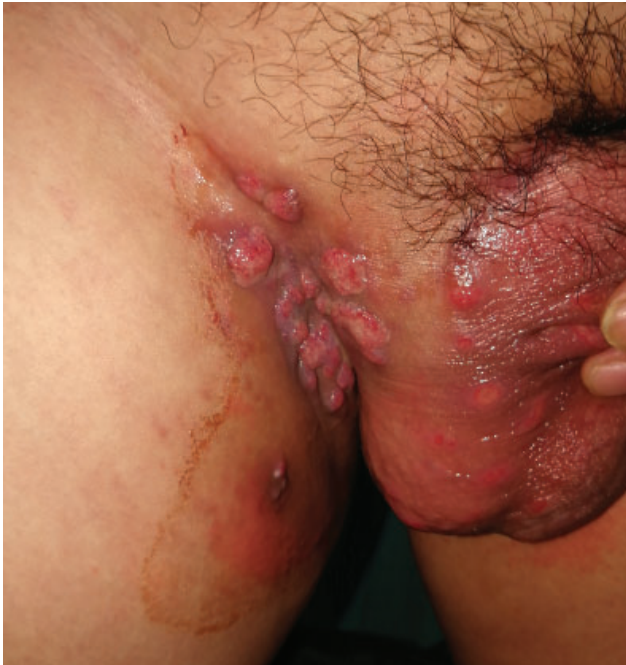doi:10.3949/cjfm.90a.22077

lata confirmed the diagnosis of secondary syphilis. The patient was treated with benzathine penicillin G 2.4 million units intramuscularly once a week for 3 weeks. His lesions entirely resolved at 6 weeks.

### ■ ACQUIRED SECONDARY SYPHILIS

Syphilis has resurfaced in recent years, with oral manifestations occurring at an increased rate.<sup>1</sup> The clinical diagnosis of acquired oral syphilis is challenging due to its diverse manifestations. It is more common in young and middle-aged men.<sup>1,2</sup>

Primary oral syphilis is characterized by a chancre, a single painless ulcerated oral lesion on the lip, labial



**Figure 2.** The lesions in the inguinal and genital regions at presentation.

commissure, or tongue.<sup>2,3</sup> In most patients, primary oral syphilis is accompanied by nontender regional lymphadenopathy.<sup>2,3</sup> The majority of cases of oral syphilis represent the secondary stage of syphilis.<sup>1,2</sup> Secondary oral syphilis usually presents as multiple subacute erosive or ulcerative lesions, mucous patches on the tongue, nodular lesions, and leukokeratotic lesions.<sup>4</sup> Tertiary syphilis is a painless localized granuloma that presents as hardened, nodular, or ulcerated lesions on the hard palate or the dorsal surface of the tongue.<sup>3</sup>

**BROAD DIFFERENTIAL DIAGNOSIS**

The range of differential diagnoses is wide and includes infectious diseases, potentially malignant oral disor-

**REFERENCES**

1. Schuch LF, da Silva KD, de Arruda JAA, et al. Forty cases of acquired oral syphilis and a review of the literature. *Int J Oral Maxillofac Surg* 2019; 48(5):635–643. doi:10.1016/j.ijom.2018.10.023
2. de Andrade BAB, de Arruda JAA, Gilligan G, et al. Acquired oral syphilis: a multicenter study of 339 patients from South America. *Oral Dis* 2022; 28(6):1561–1572. doi:10.1111/odi.13963
3. de Arruda JAA, do Valle IB, Mesquita RA, Silva TA. Oral syphilis. *J Am Acad Dermatol* 2021; 84(2):e101–e102. doi:10.1016/j.jaad.2020.09.067

ders, malignant neoplasms, and immune-mediated diseases.<sup>1,2</sup> Painful lesions that need to be considered include aphthous ulcer, traumatic ulcer, Behçet disease, inflammatory bowel disease, pemphigus vulgaris, erythema multiforme, candidiasis, and leishmaniasis.<sup>1</sup> The differential for painless lesions includes frictional keratosis, necrotizing sialometaplasia, lichen planus, sarcoidosis, tuberculosis, blastomycosis, leukoplakia, erythroplakia, squamous cell carcinoma, and soft-tissue and mesenchymal tumor.<sup>1</sup>

**VALUABLE CLUES TO DIAGNOSIS**

Symptoms of oral syphilis are nonspecific, so serological studies remain the gold standard.<sup>2,3</sup> However, we need to be aware that syphilis serology may be nonreactive in the very early stage and falsely negative due to the prozone reaction or acquired immunodeficiency syndrome. In the absence of serological evidence, the valuable clues are based on a complete medical history (unprotected sexual and orogenital contact, multiple partners, men who have sex with men, drug use, and history of other sexually transmitted diseases), careful physical examination (extraoral syphilitic manifestations), and timely pathological examination (diffuse or perivascular infiltration of lymphocytes and plasma cells). It needs to be noted that dark-field microscopic examination, immunohistochemical techniques, and silver staining are not specific to oral syphilis diagnosis due to the presence of commensal treponemes.<sup>5</sup>

Promoting awareness of oral syphilis is vital for early diagnosis, treatment, and prevention of onward transmission.

**DISCLOSURES**

The authors report no relevant financial relationships which, in the context of their contributions, could be perceived as a potential conflict of interest.

4. Lampros A, Seta V, Gerhardt P, Isnard C, Husson C, Dupin N. Oral forms of secondary syphilis: an illustration of the pitfalls set by the great imitator. *J Am Acad Dermatol* 2021; 84(2):348–353. doi:10.1016/j.jaad.2020.04.089
5. Rajlawat BP, Evans-Jones J, Triantafyllou A, Varga E, Field EA. A solitary oral ulcer. *Clin Exp Dermatol* 2011; 36(2):217–219. doi:10.1111/j.1365-2230.2010.03879.x

*Address:* Tao Chen, MD, PhD, Department of Dermatovenereology, Chengdu Second People's Hospital, 165 Caoshi Street, Chengdu 610017, Sichuan, China; 13980427003@163.com and Rong-hua Xu, MD, Institute of Dermatology, Chengdu Second People's Hospital; elvis0508@sina.com