

TABLE OF CONTENTS

FROM THE EDITOR

Born again: The many lives of metformin **523**

Repurposing old drugs for new indications is not a new drug-development strategy.

Brian F. Mandell, MD, PhD

THE CLINICAL PICTURE.....

Petaloid dermatosis affecting the scalp and genitalia **527**

The patient had seen no improvement with a 2-week course of terbinafine cream.

Taylor A. Bullock, MD; Shruti Agrawal, MD; Wilma Bergfeld, MD

THE CLINICAL PICTURE.....

Cutaneous metastasis from gastric carcinoma **533**

The patient presented with asymptomatic nodules and alopecia of the scalp 3 years after treatment for gastric adenocarcinoma.

Li-wen Zhang, MD; Wen-ju Wang, MD; Tao Chen, MD, PhD; Rong-hua Xu, MD

THE CLINICAL PICTURE.....

Persistent rectal pain leading to diffuse pustules **537**

The authors relate the workup of a 34-year-old patient with a history of syphilis and human immunodeficiency virus.

Lydia Cassard, BA; Taylor A. Bullock, MD; Wyatt Andrasik, MD; Anthony P. Fernandez, MD, PhD

1-MINUTE CONSULT

If a patient has cirrhosis, should I correct coagulation abnormalities before a minor invasive procedure? **541**

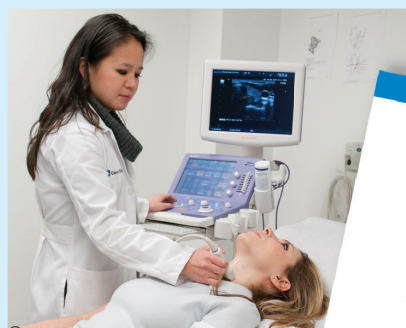Hemostatic abnormalities in cirrhosis can include thrombocytopenia, prolonged prothrombin time, prolonged activated partial thromboplastin time, elevated international normalized ratio, and decreased fibrinogen.

Emily B. Wolf, MD; Marie Plante, MD; Razvan M. Chirila, MD

CONTINUED ON PAGE 522

Upcoming Features

- SGLT-2 inhibitors in patients with heart failure and chronic kidney disease
- Portopulmonary hypertension: A focused review



CONTINUED FROM PAGE 517

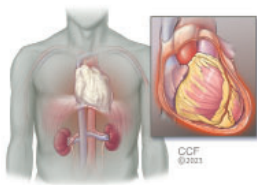
1-MINUTE CONSULT

Should I consider metformin therapy for weight loss in patients with obesity but without diabetes? 545

The authors appraise the evidence to date for weight loss with metformin in this patient population.

Paloma Rodriguez, MD; Kevin M. Pantalone, DO, ECNU, FACE; Marcio L. Griebeler, MD; Bartolome Burguera, MD, PhD

1-MINUTE CONSULT



When should pharmacologic therapies be used for uremic pericarditis? 549

If symptoms return or fail to improve with renal replacement therapy, drug therapy may be considered.

Osamah Badwan, MD; Warren Skoza, MD; Lorenzo Braghieri, MD; Ian Persits, DO; Allan L. Klein, MD, FRCP (C), FACC, FAHA, FASE, FESC

CURRENT DRUG THERAPY **CME MOC**

A practical guide for buprenorphine initiation in the primary care setting 557

The authors review changes in prescribing laws and outline buprenorphine induction protocols that can be adopted in the primary care setting.

Roberto León-Barriera, MD; Samantha Jayne Zwiebel, MD, MA; Vania Modesto-Lowe, MD, MPH

REVIEW

Mpox: Keep it on the differential 565

During its current global outbreak, mpox has exhibited novel features that clinicians should be aware of to aid recognition.

Sara L. Clemens, MD; Stuart N. Isaacs, MD

LETTER TO THE EDITOR.....

Why 25-dehydroxyvitamin D is a negative acute-phase reactant 535

Maria J. Antonelli, MD; Irving Kushner, MD; Murray Epstein, MD, FASN, FACP

DEPARTMENTS

CME Calendar 525

CME/MOC Instructions 576