

# TABLE OF CONTENTS

FROM THE EDITOR

**Continuous glucose monitoring: High-tech devices still need some low-tech backup** **585**

High-end devices that monitor patients' physiology offer many benefits, but device malfunctions and disruptions are not rare events.

Brian F. Mandell, MD, PhD

THE CLINICAL PICTURE

**Salt-and-pepper skin pigmentation** **593**

Dermoscopy of the skin lesions revealed homogeneous depigmented areas with perifollicular pigmentation.

Ramachandran Gnanasuriyan, MD; Savitha Murali, MD; Sheela Kuruvila, MD

THE CLINICAL PICTURE

**Fixed drug eruption due to ibuprofen** **597**

The patient had a 2-month history of a lesion on the left groin that caused a burning sensation.

Aneri Patel, BS; Ilana D. Breen, MD; Joshua M. Schulman, MD; Apra Sood, MD

SYMPTOMS TO DIAGNOSIS

**Abdominal pain in a patient with epistaxis, telangiectasias, and arteriovenous malformations** **601**

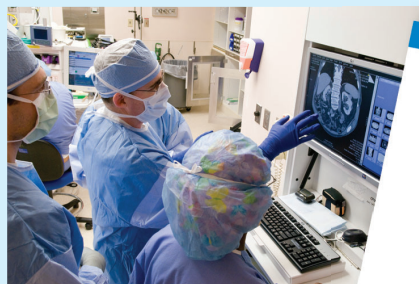The pain was radiating to the back, exacerbated by eating, and accompanied by intermittent nausea and fatigue.

Akash Mathavan, MD; Akshay Mathavan, MD; Andreas Giovanni Zori, MD; Marc Stuart Zumberg, MD; Jeb M. Justice, MD; Ali Ataya, MD

CONTINUED ON PAGE 584

## Upcoming Features

- Cervical cancer screening in high-risk patients: Clinical challenges in primary care
- How do I manage my patients with thyrotoxicosis until they see the endocrinologist?



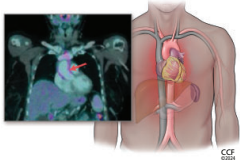
CONTINUED FROM PAGE 583

**REVIEW** .....  
**Using continuous glucose monitoring data in daily clinical practice** **611**

The authors review data elements of the Ambulatory Glucose Profile Report, a standardized format for displaying glucose monitoring data, and present a structured approach to using the data to optimize glycemic management.

Thomas W. Martens, MD; Gregg D. Simonson, PhD; Richard M. Bergenstal, MD

**REVIEW** ..... **CME** **MOC**  
**Incidentally detected noninfectious thoracic aortitis: A clinical approach** **621**



The author reviews how aortitis is detected, its many possible causes, and the workup and treatment of patients who are found to have it.

Alison H. Clifford, MD, MSc

**EDITORIAL** .....  
**Sorting out aortic aneurysms: A team enterprise** **635**

Aortic aneurysms present considerable diagnostic and treatment challenges owing to their diverse causes, incomplete understanding of pathogenesis, and variations in presentation and disease course.

Gary S. Hoffman, MD, MS, MACR

**DEPARTMENTS** .....  
**CME Calendar** **591**

**Correction** **638**

In the August 2024 issue, the article “*Helicobacter pylori*: A concise review of the latest treatments against an old foe” by Aldhalei WA, Wallace MB, Harris DM, Bi Y [Cleve Clin J Med 2024; 91(8):481–487; doi:10.3949/ccjm.91a.24031] contained an error in the first paragraph of the section titled “Proton pump inhibitor or potassium-competitive acid blockers” (pages 484–485).

**CME/MOC Instructions** **640**

**CME CREDIT TEST**

Visit **WWW.CCJM.ORG**  
 Test your knowledge  
 of clinical topics and earn  
**AMA PRA Category 1 Credit™**  
 and **ABIM MOC points**

