

# TABLE OF CONTENTS

**FROM THE EDITOR** ..... 713

**The causes of vascular insufficiency and Hickam vs Ockham** ..... 713  
 Is our reflexive search for a single explanatory diagnosis always reasonable and warranted—or is it truly “just” an academic intellectual exercise?  
 Brian F. Mandell, MD, PhD

**THE CLINICAL PICTURE** ..... 725

**Oral condylomata lata** ..... 725  
 The patient had a 3-month history of painless oral lumps and intermittent sore throat.  
 Carine J. Moezinia, MBBS, MD; Benjamin P. Zuckerman, MBBS; Ayesah Abdul-Hamid, MBChB

**1-MINUTE CONSULT** ..... 727

**How do I manage my patients with thyrotoxicosis until they see the endocrinologist?** ..... 727  
 Primary care physicians can start beta-blockers promptly for symptomatic relief, obtain radioactive iodine uptake and scan, and start methimazole if high uptake is noted.  
 Timothy W. Bodnar, MD

**COMMENTARY** ..... 731

**Matter of the heart: Prioritizing harm reduction in managing infective endocarditis associated with injection drug use** ..... 731  
 Despite specialty society recommendations, many patients do not receive treatment for substance use disorder in conjunction with heart disease treatment.  
 Akhil Anand, MD; Jared Ontko; Jyothika Yermal; Kush Sehgal, MBBS; Ashley Cantu-Weinstein

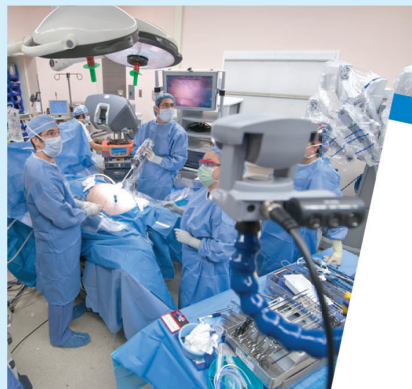**SYMPTOMS TO DIAGNOSIS** ..... 735

**A 74-year-old woman with purple toes** ..... 735  
 While the patient was undergoing treatment for livedoid vasculopathy, her toes started to become purple and she experienced persistent “stinging” pain in her feet.  
 Baila R. Elkin, MD; Megan McGervey, MD

CONTINUED ON PAGE 710

## Upcoming Features

- **Insomnia in older adults: A review of treatment options**
- **Risk-factor modification to prevent recurrent atrial fibrillation after catheter ablation**

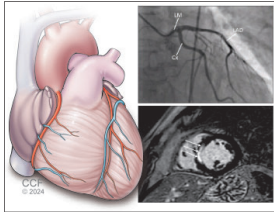


CLEVELAND  
 CLINIC  
 JOURNAL OF  
 MEDICINE

CONTINUED FROM PAGE 709

REVIEW

CME MOC



**Myocardial infarction with nonobstructive coronary arteries: 743**  
**Current management strategies**

Intracoronary imaging and cardiac magnetic resonance imaging are key tests in the diagnosis.

Kevin G. Buda, DO; Sanjoyita Mallick, DO; Louis P. Kohl, MD

EDITORIAL

**The diagnostic dilemma of myocardial infarction without obstructive coronary artery disease: Advanced imaging to the rescue! 755**

Advances in cardiac and coronary imaging and physiologic assessment now allow for a thorough, accurate workup of this condition that accounts for up to 15% of all myocardial infarctions.

Fawzi Zghyer, MD; Khaled M. Ziada, MD

REVIEW

**Managing urogenital tract disorders: 10 urology pearls for primary care physicians 762**

These pearls offer evidence-based guidance on issues that physicians are likely to encounter in practice with some frequency.

Neil M. Paige, MD, MSHS; Joseph D. Shirk, MD

LETTERS TO THE EDITOR

**Diabetic retinopathy: Screening, prevention, and treatment 723**

Ashley Lim

**In reply: Diabetic retinopathy: Screening, prevention, and treatment 723**

David D. Chong, BA; Nikhil Das, MD; Rishi P. Singh, MD

DEPARTMENTS

**CME Calendar 716**

**CME/MOC Instructions 768**

**CME/MOC CREDIT**

**Test your knowledge of clinical topics and earn AMA PRA Category 1 Credit™ and ABIM MOC points**

[www.cjfm.org/content/latest-articles-cmemoc](http://www.cjfm.org/content/latest-articles-cmemoc)

