

TABLE OF CONTENTS

FROM THE EDITOR
New *CCJM* faces and features **263**
Hospitalist James Pile, MD, and nephrologist George Thomas, MD, join the *Journal* staff as deputy editors.
Brian F. Mandell, MD, PhD

THE CLINICAL PICTURE.....
Gingival overgrowth in acute monocytic leukemia **267**
A 55-year-old man presented to the emergency department with a 2-month history of progressive gingival swelling and oral pain.
Lex Leonhardt, DO; John Harcha, MD; Alejandro Calvo, MD, FACP


COMMENTARY
Providing comfort: Caring for patients who wish to die in their home country **270**
The authors offer a framework for providing equitable care to terminally ill patients who seek the comfort of dying at home.
Kelly Ferraro, MD; Sandhya Sharma, MD; Kimberly A. Indovina, MD

EDITORIAL
Perspectives on travel and healthcare **275**
Further guidelines are needed to address the challenges faced by patients traveling to receive medical care away from their home country or returning to their home country to die.
Maan Fares, MD

CONTINUED ON PAGE 260

Upcoming Features

- **Gastroparesis for the nongastroenterologist**
- **Diabetes technology: A primer for clinicians**



CONTINUED FROM PAGE 259

1-MINUTE CONSULT

Should I refer my patient for a parathyroidectomy? 279

In patients with primary hyperparathyroidism, this decision should be individualized and not based solely on whether guideline criteria are met.

Gustavo Romero-Velez, MD; Leila Zeinab Khan, MD; Judy Jin, MD

1-MINUTE CONSULT

Does every patient with lactational mastitis require antibiotic treatment? 283

Not all do. Depending on the duration and severity of symptoms, some patients can be managed conservatively.

Abigail Wink, BS; Jameson A. Mitchell, BA; Suet Kam Lam, MD, MPH, MS, IBCLC, FAAP; Heidi Szugye, DO, NABBLM-C, IBCLC, FAAP

1-MINUTE CONSULT

Do I always need a central venous catheter to administer vasopressors? 287

Although generally preferred, central venous catheters carry risks such as procedural complications, infection, and thrombosis. Clinicians must assess, case by case, whether a peripheral intravenous catheter can be used.

Zainab J. Gandhi, MD; Siddharth Dugar, MD, FCCP, FCCM, FASE; Ryota Sato, MD, EDIC

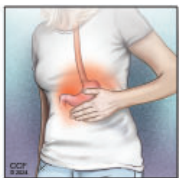CURRENT DRUG THERAPY **CME MOC**

Reducing the risks when using benzodiazepines to treat insomnia: A public health approach 293

The authors review measures for preventing harm before benzodiazepines are prescribed, decreasing harm within 4 weeks after they are prescribed, and limiting harmful effects of long-term prescribing.

Vania Modesto-Lowe, MD, MPH; Margaret M. Chaplin, MD; Roberto León-Barriera, MD; Lakshit Jain, MD

REVIEW **CME MOC**



Functional dyspepsia: How to manage the burn and the bloat 301

The authors discuss how to diagnose and treat the 2 subtypes of functional dyspepsia: epigastric pain syndrome (burning and pain) and postprandial distress syndrome (bloating and satiety).

Scott Gabbard, MD; Nina Vijayvargiya, BS

SYMPTOMS TO DIAGNOSIS

Simultaneous hemorrhage and venous thrombosis in a patient with systemic lupus erythematosus 308

After undergoing hip arthroplasty, the patient had hematoma formation in the pelvis, active bleeding from the surgical site, and a prolonged activated partial thromboplastin time. Careful evaluation led to the diagnosis of an acquired bleeding disorder.

Binoy Yohannan, MD; Natalie A. Montanez, FNP-C; Miguel A. Escobar, MD

DEPARTMENTS

CME Calendar 265

CME/MOC Instructions 318