

TABLE OF CONTENTS

FROM THE EDITOR

Foxglove, not quite gone or forgotten **458**

Digoxin use has waned dramatically over the past decades, with good reason, but for select patients, it may be a very reasonable option.

Brian F. Mandell, MD, PhD

THE CLINICAL PICTURE.....

Persistent erosions of the glans penis and foreskin **463**

A 66-year-old man presented with an 8-month history of persistent erosions of the glans penis and foreskin with slight itching and pain.

Zheng Gu, MD; Dong-Lai Ma, MD, PhD

1-MINUTE CONSULT

What fluids should I order for my patient with acute pancreatitis? **466**

Recent data show that moderate fluid resuscitation is associated with fewer adverse events and that lactated Ringer's may be superior to normal saline.

Anusha Agarwal, MD; Arjun Chatterjee, MD; Prabhleen Chahal, MD

SYMPTOMS TO DIAGNOSIS

Recurrent syncope in a 62-year-old man **473**

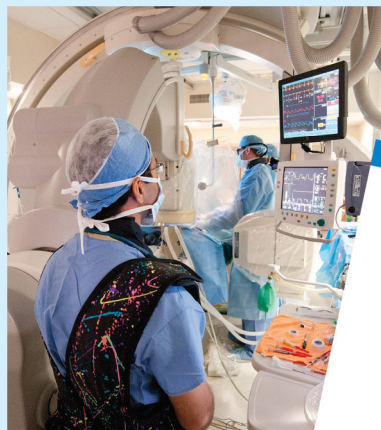The patient experienced 2 episodes of syncope over 4 weeks, had a history of recurrent carpal tunnel syndrome, and had ankle edema for the previous 18 months.

Cindy Hsin-Ti Lin, MD; Michael Sheu, MD; Faiz Anwer, MD

CONTINUED ON PAGE 457

Upcoming Features

- Primary adrenal insufficiency in adults: When to suspect, how to diagnose and manage
- Should I refer my patients for renal denervation?



CLEVELAND
CLINIC
JOURNAL OF
MEDICINE

CONTINUED FROM PAGE 454

REVIEW
***Helicobacter pylori*: A concise review of the latest treatments against an old foe** **481**

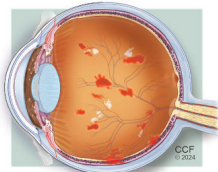
H pylori eradication regimens are tailored based on the presence of effective empiric therapy (local cure rates $\geq 90\%$ for a given regimen) or antimicrobial susceptibility testing.

Wafa A. Aldhaleei, MBBCh, MSc, MPH; Michael B. Wallace, MD, MPH; Dana M. Harris, MD; Yan Bi, MD, PhD

REVIEW **CME MOC**
Digoxin is still useful, but is still causing toxicity **489**

The authors review the presentation of digoxin toxicity, its mechanisms and predisposing factors, and its medical management.

Alejandro Durán Crane, MD; Michael Militello, PharmD, BCPS; Michael D. Faulx, MD



REVIEW
Diabetic retinopathy: Screening, prevention, and treatment **503**

Effective screening processes, timely referrals, and strategic diabetes management are essential to prevent and mitigate the consequences of diabetic retinopathy.

David D. Chong, BA; Nikhil Das, MD; Rishi P. Singh, MD

DEPARTMENTS
CME Calendar **460**
CME/MOC Instructions **512**

CME CREDIT TEST

Visit WWW.CCJM.ORG
 Test your knowledge
 of clinical topics and earn
AMA PRA Category 1 Credit™
 and **ABIM MOC points**

