

TABLE OF CONTENTS

FROM THE EDITOR 263

The gift of lasting immunity 263
 Measles vaccine–induced immunity, although not necessarily lifelong for all individuals, is quite durable.
 Brian F. Mandell, MD, PhD

THE CLINICAL PICTURE..... 271

Tinea incognito 271
 This atypical form of dermatophyte infection is caused by local immune suppression from systemic or topical corticosteroids.
 Soniya Shony, MBBS; Carol Lobo, MBBS, MD; Sowmya Kaimal, MD

1-MINUTE CONSULT 273

What diagnostic tests should be done after discovering clubbing in a patient without cardiopulmonary symptoms? 273
 Computed tomography of the patient’s chest is indicated based on the robust association between clubbing and intrathoracic malignancy.
 Karthik Meiyappan Udayappan, MD; Christopher V. Anstine, MD

1-MINUTE CONSULT 279

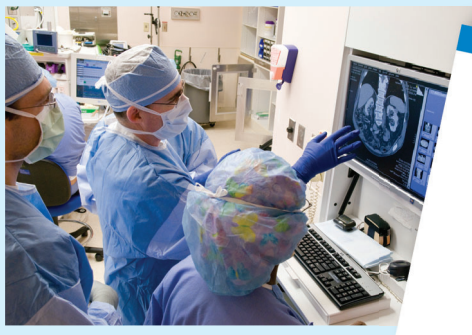Does my adult patient need a measles vaccine? 279
 Possibly. Adults without acceptable presumptive evidence of immunity to measles should receive 1 dose of the measles-mumps-rubella vaccine, and 2 doses are recommended for adults in special situations.
 Kaitlyn R. Rivard, PharmD

1-MINUTE CONSULT 285

Do I need to treat supine hypertension in my hospitalized patient? 285
 Inpatients with an elevated supine blood pressure should be evaluated for orthostatic changes before treatment is considered.
 Katherine Sherman, MD; Robert Lichtenberg, MD

Upcoming Features

- Direct oral anticoagulants: Common challenging scenarios in everyday practice
- Managing the side effects of sodium-glucose cotransporter 2 inhibitors



CLEVELAND
 CLINIC
 JOURNAL OF
 MEDICINE

GUIDELINES TO PRACTICE

CME MOC

New atrial fibrillation guideline: Modify risk, control rhythm, prevent progression 291

Key updates in the new American guideline include recommendations for aggressive lifestyle and risk-factor modifications, annual assessment of thromboembolic risk, and early rhythm control.

Laura A. Campbell, MD; Jessica P. Ammon, DO; Rachana Kombathula, MD; Naa'irah Muhammad, MD; Christopher D. Jackson, MD

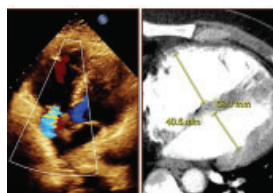
EDITORIAL

The beat goes on: Highlights from the new American and European A-fib guidelines 297

The authors discuss and compare the latest atrial fibrillation guidelines from American and European medical societies.

Sandra Howell, MBBS, MEd, MSc, MPhil; Alphonsus Liew, MBBS; Christopher Aldo Rinaldi, MD

REVIEW

**Managing right ventricular failure in the setting of pulmonary embolism** 301

The authors review current management strategies, including medical, percutaneous interventional, and surgical options, and discuss recent advances in the field.

Sharmeen Sorathia, MD; Anibelky Almanzar, MD; Abhishek Bhandiwad, MD; Phoo Pwint Nandar, MD

REVIEW

Alpha-gal syndrome: Recognizing and managing a tick-bite-related meat allergy 311

Alpha-gal syndrome is an emerging allergic condition in which immunoglobulin E-mediated symptoms are triggered a few hours after an affected person consumes mammalian meat.

Zehra Naseem, MD; Aun Muhammad, MD; Arjun Chatterjee, MD; Alberto Rubio-Tapia, MD

LETTERS TO THE EDITOR

In defense of the anion gap 269

Michael Emmett, MD

In Reply: In defense of the anion gap 269

Paloma Rodriguez Alvarez, MD; Vicente T. San Martin, MD; Oscar L. Morey-Vargas, MD

DEPARTMENTS

CME Calendar 266**CME/MOC Instructions** 320