

Karthik Meiyappan Udayappan, MD

Senior Associate Consultant, Department of Medicine, Division of General Internal Medicine, Mayo Clinic, Rochester, MN; Instructor of Medicine, Mayo Clinic College of Medicine and Science, Rochester, MN

Christopher V. Anstine, MD

Consultant, Department of Medicine, Division of General Internal Medicine, Mayo Clinic, Rochester, MN; Assistant Professor of Medicine, Mayo Clinic College of Medicine and Science, Rochester, MN



Q: What diagnostic tests should be done after discovering clubbing in a patient without cardiopulmonary symptoms?

A 50-year-old woman presents with bilateral ankle and knee swelling along with morning stiffness in both knees for the past several months. She has a remote 15-pack-year smoking history and began using electronic cigarettes 2 years ago but denies cough, shortness of breath, or orthopnea. She has no known cardiac or pulmonary diseases. Vital signs are normal. Physical examination is significant for swelling of her ankles without warmth or redness. Bilateral fingernail clubbing is noted (**Figure 1**). Given that clubbing is detected on examination, should chest imaging be obtained despite an absence of cardiopulmonary symptoms? Are any other evaluations indicated?

A: Computed tomography of the chest is indicated based on the robust association of clubbing with intrathoracic malignancy. Chest computed tomography would also evaluate for other intrathoracic conditions associated with clubbing, including interstitial lung disease.¹ In addition, this patient's ankle swelling and knee stiffness could represent hypertrophic osteoarthropathy, and radiographs of the tibia, fibula, and ankle joints are indicated. If the radiographs do not show corroborating periosteal bone formation, bone scintigraphy should be considered, as it is more sensitive in detecting these changes.

■ DETECTING CLUBBING ON EXAMINATION

Most clinicians can detect advanced clubbing. However, older studies suggest that the precision and interrater reliability of the physical examination for

doi:10.3949/cjcm.92a.24052

clubbing is fair to moderate at best.² Clubbing, unlike other examination findings such as ascites or splenomegaly, does not have a gold standard radiographic correlate to validate against. Instead, it depends on careful observation of changes to the depth of the distal phalanx and altered nail-fold angles. In the past, plaster casts, shadowgraphs, and calipers were used to obtain the quantitative measurements that define clubbing.²

Different views of our patient's fingernails are presented in **Figure 1**. Early clubbing can be difficult to identify from a superior view (**Figure 1A**). The changes that define clubbing are easier to discern on profile view (**Figure 1B**). In our clinical experience, measurement of the distal phalanx depths has higher reproducibility and interrater reliability than an estimation of nail-fold angles (**Figure 1C**).

Distal phalanx depth

If the depth of the digit is larger at the nail fold than at the distal interphalangeal joint, clubbing is present. This is easier to observe from a side view, or profile view, rather than a superior view, as seen in our patient.

Nail-fold angles

The *hyponychial angle* is formed by the intersection of lines drawn from the back surface of the distal interphalangeal joint to the proximal nail fold and from the proximal nail fold to the hyponychium (skin under end of nail plate). This angle is typically a straight line (180 degrees) in a normal finger. If the hyponychium is below the line drawn from the distal interphalangeal joint to the proximal nail fold, the hyponychial angle is greater than 180 degrees, which suggests clubbing.

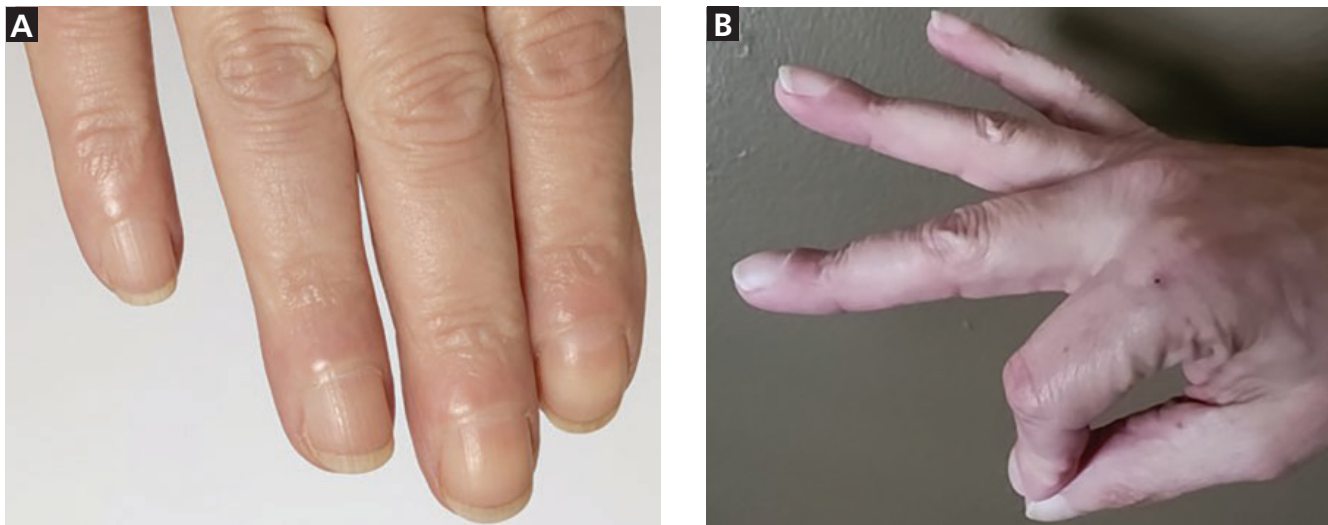
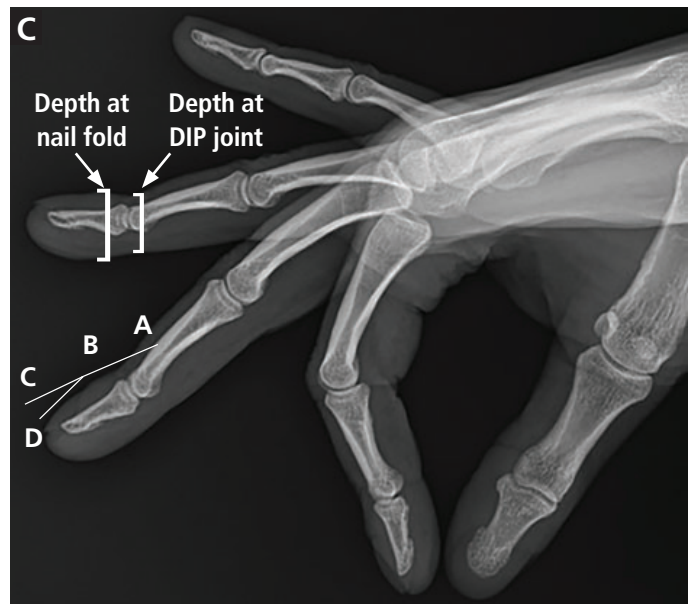


Figure 1. Views of the patient's fingers and fingernails. (A) Superior view of early clubbing. (B) Profile view of early clubbing. (C) The depth at the nail fold is greater than the depth at the distal interphalangeal joint (DIP), which confirms the presence of clubbing. Point D (the *hyponychium*) is lower than the extension of line AB created from the DIP joint to the nail fold. This angle ABD (*hyponychial angle*) is greater than 180 degrees, also confirming clubbing. The profile angle (or the *Lovibond angle*) is visually the hardest to estimate. This angle, formed by ABC, is also greater than 180 degrees, which would prevent a diamond-shaped window from appearing when this digit is opposed nail-to-nail with the corresponding digit on the opposite hand with angle ABC greater than 180 degrees (*Schamroth sign*).



The *profile angle*, also known as the *Lovibond angle*, is the angle at which the nail exits the nail fold. It is typically harder to estimate on examination. Normal fingernails placed back-to-back with the opposing nails create a diamond-shaped window. In clubbed nails, this window is not present due to the increase in the profile angle—referred to as a positive *Schamroth sign*.

In addition to visual inspection, distal phalanx depth can be assessed by palpating the distal interphalangeal joint with the examiner's thumb and index finger and subsequently sliding the fingers distally. If the examiner perceives an increase in the space between the thumb and index finger, then clubbing is present.

THE RELATIONSHIP OF CLUBBING TO HYPERTROPHIC OSTEOARTHROPATHY

Clubbing can sometimes occur as part of a triad of symptoms that comprise hypertrophic osteoarthropathy, a systemic syndrome. Hypertrophic osteoarthropathy has 3 manifestations: clubbing, synovial effusions, and periosteal bone formation in tubular bones including the radius, ulna, tibia, and fibula.³ Formal diagnostic criteria require the presence of clubbing combined with radiographic evidence of periosteal bone formation in tubular bones. In other words, all patients with hypertrophic osteoarthropathy have clubbing, but only a small percentage of patients with clubbing

have hypertrophic osteoarthropathy. Some patients with hypertrophic osteoarthropathy may report deep-seated, severe bone pain most prominently in the lower extremities along with joint swelling, while others do not experience pain and may not even be aware of the clubbing changes in their fingernails.³

Laboratory testing and imaging studies

Current hypotheses on the pathogenesis of clubbing implicate cytokines such as transforming growth factor beta, platelet-derived growth factors from megakaryocytes, and vascular endothelial growth factor.⁴ Currently, levels of these cytokines or bone turnover markers like alkaline phosphatase are not used to diagnose hypertrophic osteoarthropathy. If a patient with clubbing has bone pain or swelling, plain radiography of the bones suspected to be involved is indicated. If periosteal bone formation is not found and suspicion for hypertrophic osteoarthropathy remains high, bone scintigraphy should be considered as it is extremely sensitive in finding changes seen in hypertrophic osteoarthropathy.⁵

Plain radiographs of bones in patients with both clubbing and bone-related symptoms help establish the diagnosis of hypertrophic osteoarthropathy and exclude other causes of bone-related symptoms, such as metastasis. This can also guide symptomatic management, such as bisphosphonate therapy for hypertrophic osteoarthropathy-related bone pain. However, we do not suggest routine use of plain radiographs of long bones in patients with clubbing who do not have bone-related symptoms, because, in the absence of these symptoms, it is not known if there is a clinically actionable difference between patients who have clubbing only compared with patients who have clubbing as well as asymptomatic radiographic changes of hypertrophic osteoarthropathy.

■ DISEASES ASSOCIATED WITH CLUBBING

Hypertrophic osteoarthropathy can occur as a primary disease or secondary to other disease processes.⁵ Primary hypertrophic osteoarthropathy is a rare inherited condition that manifests with clubbing, skin changes such as progressive thickening and furrowing wrinkling of skin on the forehead and hyperhidrosis, and periosteal bone formation. Secondary hypertrophic osteoarthropathy is much more common, comprising 95% to 97% of cases.

Clubbing observed on only 1 hand is commonly associated with hemiplegia or a local vascular disease, such as dialysis fistulas or arterial aneurysms.¹ Bilateral clubbing is associated with an extensive list of diseases, with intrathoracic disease, including lung cancer as a paraneoplastic phenomenon, being the most common.⁵ It should be noted that, although paraneoplastic syn-

dromes are more common in small cell lung carcinoma than in non-small cell lung carcinoma, non-small cell lung carcinoma is more commonly linked with clubbing. Specifically, clubbing is observed in approximately 35% of patients with non-small cell lung carcinoma vs 4% of patients with small cell lung carcinoma.¹

Other intrathoracic causes include the following^{1,2,5}:

- Metastatic lung nodules
- Interstitial lung disease
- Bronchiectasis
- Chronic mycobacterial or fungal infection
- Cyanotic congenital heart disease
- Infective endocarditis
- Esophageal carcinoma.

Extrathoracic diseases associated with bilateral clubbing include cirrhosis, inflammatory bowel disease, celiac disease, and thyroid acropachy.

Notably, chronic obstructive pulmonary disease is not associated with clubbing, but it is itself an independent risk factor for primary lung cancer, which is strongly associated with clubbing. More than 90% of cases of secondary hypertrophic osteoarthropathy are associated with malignancies or other chronic pulmonary diseases.⁶

■ SEARCHING FOR THE CAUSE OF CLUBBING

If the clubbing, within or outside the context of hypertrophic osteoarthropathy, is new, bilateral, and asymptomatic, we recommend chest computed tomography because of the strong association between clubbing and lung malignancy or chronic lung disease.⁶ If access to chest computed tomography is delayed, chest radiography can be done, bearing in mind that chest computed tomography has higher sensitivity (93.8% vs 73.5%) in detecting nodules and malignancy at earlier stages.^{7,8} Otherwise, efforts to identify the cause of clubbing should be driven by symptoms and signs. For example, a patient found to have clubbing with symptoms of intermittent bloody diarrhea will require an evaluation for inflammatory bowel disease. If a patient already has a condition known to be associated with clubbing but newly develops clubbing, we still suggest computed tomography of the chest to exclude an emerging intrathoracic malignancy. **Figure 2** presents our suggested approach to the evaluation of clubbing.

Computed tomography of our patient's chest showed a necrotic mass in the apical right lung. Pathology revealed lung adenocarcinoma. Plain radiographs of the tibia and fibula showed bilateral periosteal new bone with cortical thickening. Nuclear bone scan showed radiotracer uptake involving the tibial and fibular cortices, corresponding to periosteal bone formation. Both

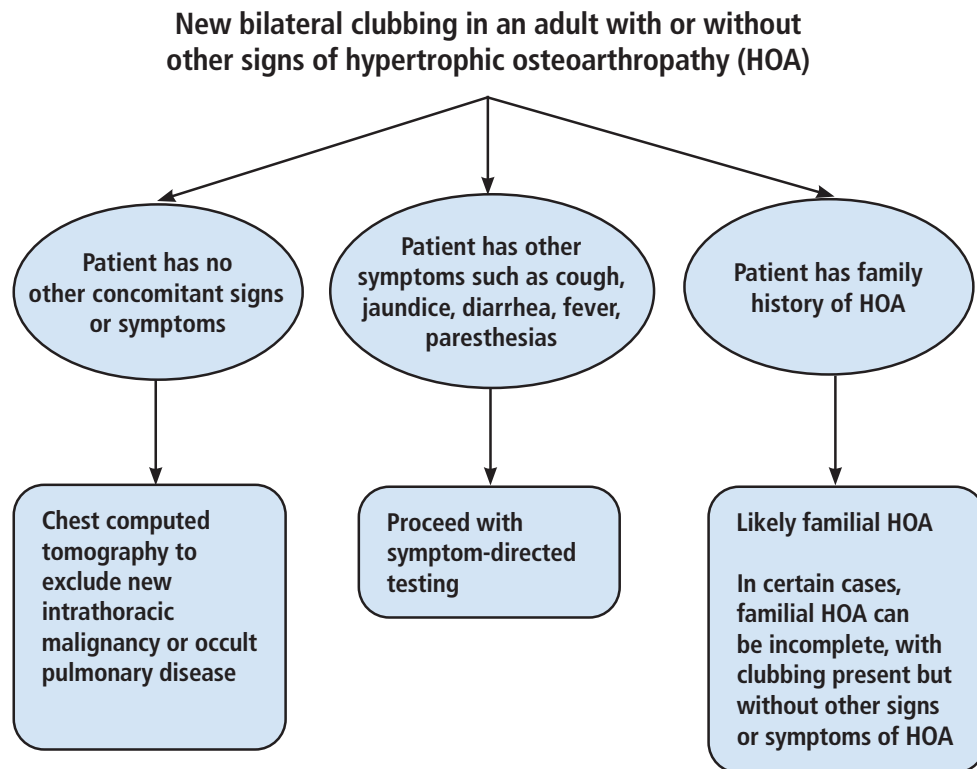


Figure 2. Suggested approach to evaluation of bilateral clubbing.

the plain radiographs and the nuclear bone scan confirmed the presence of hypertrophic osteoarthropathy.

THE BOTTOM LINE

If the presence of clubbing is uncertain, a profile view of the distal phalanx with a focus on the change in depth is more practical than estimation of nail-fold angles. If the depth increases from the distal interphalangeal joint to the nail fold, clubbing is present. If leg or wrist pain with swelling is present, plain radiographs with or without bone scintigraphy are indicated to diagnose hypertrophic osteoarthropathy. All 3 features of hyper-

trophic osteoarthropathy (clubbing, periosteal bone formation, synovitis) are not always present. Aggressive evaluation of new, asymptomatic bilateral clubbing with or without hypertrophic osteoarthropathy presents an opportunity to diagnose malignancy earlier. We suggest chest computed tomography as the first step in searching for the cause, even in patients without cardiopulmonary symptoms.

DISCLOSURES

The authors report no relevant financial relationships which, in the context of their contributions, could be perceived as a potential conflict of interest.

REFERENCES

1. Spicknall KE, Zirwas MJ, English JC 3rd. Clubbing: an update on diagnosis, differential diagnosis, pathophysiology, and clinical relevance. *J Am Acad Dermatol* 2005; 52(6):1020–1028. doi:10.1016/j.jaad.2005.01.006
2. Myers KA, Farquhar DR. The rational clinical examination. Does this patient have clubbing? *JAMA* 2001; 286(3):341–347. doi:10.1001/jama.286.3.341
3. Pineda C, Martínez-Lavin M. Hypertrophic osteoarthropathy: what a rheumatologist should know about this uncommon condition. *Rheum Dis Clin North Am* 2013; 39(2):383–400. doi:10.1016/j.rdc.2013.02.008
4. Martínez-Lavin M. Hypertrophic osteoarthropathy. *Best Pract Res Clin Rheumatol* 2020; 34(3):101507. doi:10.1016/j.berh.2020.101507

5. Yap FY, Skalski MR, Patel DB, et al. Hypertrophic osteoarthropathy: clinical and imaging features. *Radiographics* 2017; 37(1):157–195. doi:10.1148/rg.2017160052
6. Sarkar M, Mahesh DM, Madabhavi I. Digital clubbing. *Lung India* 2012; 29(4):354–362. doi:10.4103/0970-2113.102824
7. National Lung Screening Trial Research Team, Church TR, Black WC, et al. Results of initial low-dose computed tomographic screening for lung cancer. *N Engl J Med* 2013; 368(21):1980–1991. doi:10.1056/NEJMoa1209120
8. Altorki N, Kent M, Pasmantier M. Detection of early-stage lung cancer: computed tomographic scan or chest radiograph? *J Thorac Cardiovasc Surg* 2001; 121(6):1053–1057. doi:10.1067/mtc.2001.112827

Address: Karthik Meiyappan Udayappan, MD, Department of Medicine, Division of General Internal Medicine, Mayo Clinic, 200 1st Street NW, Rochester, MN 55901; udayappan.meiyappan@mayo.edu