

TABLE OF CONTENTS

FROM THE EDITOR

Allopurinol hypersensitivity is rare, bad, and partially avoidable, but allopurinol can still be used effectively **326**

The shadow of the 1984 Hande et al guidelines still hangs over clinical decision-making when managing allopurinol dosing in patients with gout and chronic kidney disease.

Brian F. Mandell, MD, PhD

THE CLINICAL PICTURE.....

Severe cutaneous reaction induced by allopurinol **331**

Three weeks after starting allopurinol for gout, an 86-year-old woman presented with a maculopapular rash and painful blistering and erosions of the oral mucosa.

Pietro Bocchi, MD; Lorenza Terroni, MD; Corrado Pattacini, MD

THE CLINICAL PICTURE.....

Amoxicillin rash in infectious mononucleosis **335**

A 23-year-old woman developed a rash on the day she completed a 10-day course of amoxicillin for group A streptococcal infection.

Yasuhiro Kano, MD

1-MINUTE CONSULT

Should I start anticoagulation in my patient newly diagnosed with pulmonary hypertension? **339**

The decision hinges on the subtype of pulmonary hypertension the patient has.

Tark Abou-Elmagd, MD, MSc, MBBCh; Shraddha Narechania, MD

EDITORIAL

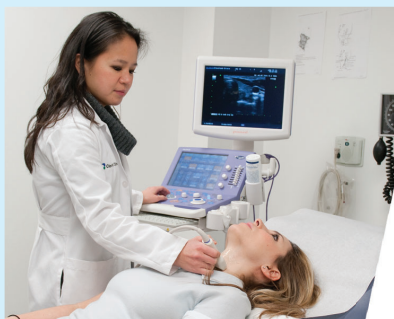
Nitrogen: The unsung hero of vascular physiology **344**

The seventh element on the periodic table—nitrogen—may not come to mind often in day-to-day medical practice, but it is more exciting than you might think.

Adam J. Brown, MD

Upcoming Features

- **Fecal microbiota transplantation: Current evidence, safety, and future directions**
- **Managing the side effects of sodium-glucose cotransporter 2 inhibitors**



1-MINUTE CONSULT

My adult patient’s hypercholesterolemia is not responding to statins—what’s next? 347

Further investigation is needed when patients do not meet their target low-density lipoprotein cholesterol levels with statin therapy alone.

Faiiq N. Aslam, MD; Mohamed G. Ibrahim, DO; Razvan Chirila, MD

REVIEW

CME MOC

Direct oral anticoagulants: Challenging prescribing scenarios in everyday practice 353

Preapproval trials of direct oral anticoagulants excluded patients with extreme body weight and advanced kidney and liver disease and those who had undergone bariatric surgery. Cautious decision-making in these patients is warranted.

Syed Bukhari, MD, MHA; Mohamed Ghoweba, MD; Syed Zamrak Khan, MD; Ammar Saati, MD; Marcelo Gomes, MD

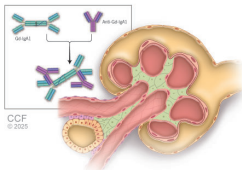
REVIEW

High-output heart failure from arteriovenous dialysis access: A structured approach to diagnosis and management 362

Arteriovenous high-output heart failure is likely underdiagnosed because many clinicians are uncertain about when and how to evaluate for it.

Maximilian C. Volk, DO; Bianca Honnekeri, MD; Joanna Ghobrial, MD; Mazen Hanna, MD; Sanjeeb Bhattacharya, MD; Lee Kirksey, MD; J. Emanuel Finet, MD; Heba Wassif, MD, MPH

REVIEW



IgA nephropathy: Update on pathogenesis and treatment 373

Renin-angiotensin-aldosterone system inhibitors or corticosteroids remain the cornerstone of therapy, but new agents targeting the different “hits” in the pathogenesis of IgA nephropathy are being introduced.

Seshma Ramsawak, MD; Scott Cohen, MD; Andrea Linares, DO; Corey Cavanaugh, DO

DEPARTMENTS

CME Calendar 329

CME/MOC Instructions 384

CME/MOC CREDIT

Test your knowledge of clinical topics and earn AMA PRA Category 1 Credit™ and ABIM MOC points

www.ccmj.org/content/latest-articles-cmemoc

