

TABLE OF CONTENTS

FROM THE EDITOR

Getting stuck on a name: An example of an eponymous syndrome 131

Debate continues about whether we should continue to use eponymous diagnostic nomenclature or shift entirely to an anatomic or pathophysiologic descriptive terminology.

Brian F. Mandell, MD, PhD

THE CLINICAL PICTURE

'Boxing glove' hands in a patient initially diagnosed with RS3PE syndrome 135

The patient had edema that limited finger flexion, impairing daily tasks such as putting on socks.

Hirokazu Takai, MD; Seiko Takai, MD

THE CLINICAL PICTURE

Ogilvie syndrome (colonic pseudo-obstruction) 145

Two days after the patient underwent surgery to repair a left femur fracture, his abdomen became markedly distended, but without pain.

Mohamed Adam Ali, MBBS, BSc; Zahra Al-Badry; Fatima M. H. Ali, MBBS, MRCPCH

THE CLINICAL PICTURE

Westermarck sign (focal oligemia) in pulmonary embolism 149

The patient's chest radiograph showed a focal area of reduced blood flow in the middle and upper zones of the right lung.

Yusuke Namba, MD, PhD; Yusuke Kawai, MD, PhD

COMMENTARY

Alpha-1 antitrypsin deficiency: A persistently underrecognized condition 153

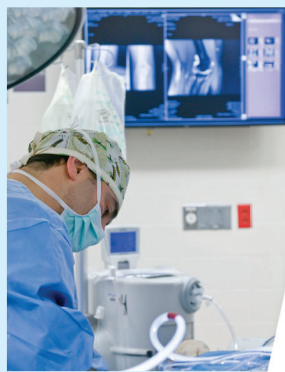Detecting alpha-1 antitrypsin deficiency early is imperative because diagnostic delay is associated with harm, including worsened clinical status and impaired survival.

James K. Stoller, MD, MS

CONTINUED ON PAGE 130

Upcoming Features

- **Complement inhibition:
A whole new world**
- **How should I evaluate allergic disease
in patients with asthma?**



CLEVELAND
CLINIC
JOURNAL OF
MEDICINE

CONTINUED FROM PAGE 123

SYMPTOMS TO DIAGNOSIS

A 24-year-old man with severe hemolytic anemia and variable Coombs test results **159**

The patient was admitted to the hospital because of dark urine, jaundice, fatigue, and confusion.

Sindu Iska, MD; María Herrán, MD; You Li, MD; María Teresa Bejarano, MD; Chakra P. Chaulagain, MD; Chieh-Lin Fu, MD

GUIDELINES TO PRACTICE

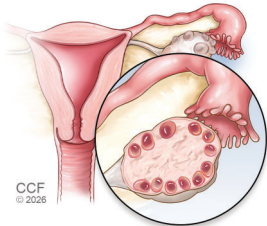
CME MOC

Optimizing bowel preparation for colonoscopy: Updated consensus recommendations **169**

Key updates in the 2025 guideline include simplifying dietary restrictions to low-residue foods for a single day before colonoscopy, preferring 2-L over 4-L preparation regimens, and universally recommending split-dose administration.

Hussam Kawas, MD; Claire Beveridge, MD

REVIEW



CCF © 2026

Polycystic ovary syndrome: An update on diagnosis and management **176**

Because this syndrome affects health throughout the lifespan, long-term management is essential, not only to control symptoms but also to prevent associated metabolic conditions.

Nayoung Sung, MD, MSCP; Jawaria Amir, MD; Ula Abed Alwahab, MD; Tommaso Falcone, MD

DEPARTMENTS

CME Calendar **133**

CME/MOC Instructions **184**

CME/MOC CREDIT

Test your knowledge of clinical topics and earn **AMA PRA Category 1 Credit™** and **ABIM MOC points**

www.ccjm.org/content/latest-articles-cmemoc

