

TABLE OF CONTENTS

FROM THE EDITOR

'Even when the wound is healed, the scar remains' 255

Persistent or repetitive inflammatory or ischemic insults to internal organs may lead to progressive scarring that culminates in organ failure.

Brian F. Mandell, MD, PhD

THE CLINICAL PICTURE

Iris roseola: A diagnostic clue in neurosyphilis 259

The patient had a 3-week history of decreased vision in the left eye, with a best-corrected visual acuity of 20/100.

Victor Alegre-Ituarte, MD, PhD; Elena Franz-Lacomba, MD

THE CLINICAL PICTURE

Varicella-zoster virus transmission from herpes zoster exposure 261

Two weeks before the patient developed fever and a rash, his mother had developed herpes zoster on her torso.

Ayano Takeiri, MD; Kentaro Ishikura, MD; Yoshitaka Tomoda, MD, PhD

COMMENTARY

Fighting ageism: Preserving patient agency in critical care 263

To avoid falling into ageism bias, we must maintain a framework grounded in respect for the patient, one that deliberately centers on the patient's voice.

Astefanos Al-Dalakta, MD; Ruth Diana Lee, MD; Chadi Tabaja, MD; Issam Motairek, MD; Eduardo Mireles-Cabodevila, MD

SYMPTOMS TO DIAGNOSIS

Unexplained liver injury: Searching for the cause 267

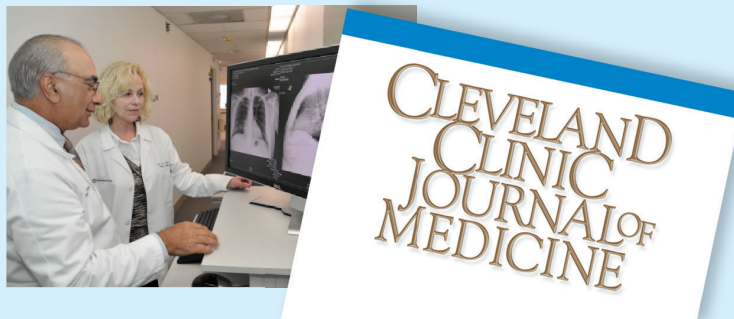The patient presented with persistent low back pain, nausea, poor appetite, and an unintentional weight loss of more than 30 lb over the previous 6 weeks.

Mohamed Eldib, MD; William D. Carey, MD; Blazenska Skugor, MD

CONTINUED ON PAGE 254

Upcoming Features

- Using KDIGO risk categories to manage chronic kidney disease
- Benzodiazepine tapering: Review of the joint clinical practice guideline



CONTINUED FROM PAGE 253

INTERPRETING KEY TRIALS

FINEARTS-HF: Improving outcomes in heart failure with preserved or mildly reduced ejection fraction **273**

FINEARTS-HF established finerenone as an effective medical therapy to reduce hospitalizations for heart failure in patients with HFpEF or HFmrEF.

Salman Salahuddin, MD, DM, MRCP (UK)

REVIEW

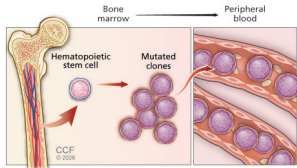
CME MOC

Reversing fibrosis in metabolic dysfunction–associated steatohepatitis—beyond telling patients to lose weight **279**

Weight loss of at least 10% is associated with fibrosis regression in most patients, but losing this amount of weight and keeping it off is challenging, making pharmacologic and procedural interventions essential tools in clinical practice.

Leandro Sierra, MD; Lily Liu, MD; Akash Khurana, MD; Roma Patel, MD; Arjun Chatterjee, MD; Stephen Firkins, MD; Roberto Simons-Linares, MD

REVIEW



Clonal hematopoiesis of indeterminate potential and heart disease: What every internist needs to know **289**

Clonal hematopoiesis is increasingly recognized as a driver of different types of heart disease, including ischemic heart disease, heart failure, arrhythmias, and nonischemic cardiac inflammation.

Ohad Oren, MD, MPH; Abhay Singh, MD; Hetty E. Carraway, MD, MBA; Luke J. Laffin, MD; Steven E. Nissen, MD

REVIEW

Sex-specific risk factors for stroke in women: Focus on the 2024 AHA/ASA guideline **297**

Sex-specific factors like adverse pregnancy outcomes and premature and early menopause play a critical and often underrecognized role in shaping lifetime stroke risk in women.

Paru S. David, MD, MSCP; Hannah Nordhues, MD, MSCP; Suneela Vegunta, MD, MSCP

DEPARTMENTS

CME Calendar **257**

CME/MOC Instructions **304**

CME/MOC CREDIT

Test your knowledge of clinical topics and earn AMA PRA Category 1 Credit™ and ABIM MOC points

www.cjcm.org/content/latest-articles-cmemoc

